



F
I
E
L
D
E

G
U
I
D
E

DISEASES AND PARASITES OF MARINE MAMMALS OF THE EASTERN ARCTIC




**F
I
E
L
D
G
U
I
D
E** **DISEASES AND
PARASITES OF
MARINE MAMMALS
OF THE EASTERN
ARCTIC**

Kara L. Vlasman & G. Douglas Campbell



CANADIAN COOPERATIVE
WILDLIFE HEALTH CENTRE



Publication of this book is the result of a collaborative effort between the Canadian Cooperative Wildlife Health Centre and the Inuit Tapiriit Kanatami. Funding was provided by the Northern Contaminants Program of the Department of Indian Affairs and Northern Development of the Government of Canada. The views expressed herein are those of the authors and do not necessarily reflect the views of the Inuit Tapiriit Kanatami or any of its subagencies.

All rights reserved

Copyright © 2003 Canadian Cooperative Wildlife Health Centre, University of Guelph, Guelph, ON.

Printed in Canada

Book design by Kara Vlasman


Acknowledgements

Preparation of this handbook would not have been possible without the assistance of many people. In particular Dr. Joe Geraci and Valerie Lounsbury at the National Aquarium in Baltimore, Maryland and Dr. Lena Measures at the Maurice Lamontagne Institute of Fisheries and Oceans Canada in Mont Joli, Quebec generously provided access to their photographic collections, expert advice on marine mammal diseases and parasites, and editorial guidance. Others who contributed in similar fashion include Ole Nielsen, Department of Fisheries and Oceans Canada; Dr. Ian Stirling, Canadian Wildlife Service; Dr. Stephen Atkinson, Nunavut Department of Sustainable Development; Dr. Bill Doidge, Nunavik Research Centre; Dr. David St. Aubin, Mystic Marinelife Aquarium; and Drs. Ian Barker, Marc Cattet, Ted Leighton, and Pierre-Yves Daoust of the Canadian Cooperative Wildlife Health Centre. We are also grateful to Eric Loring at the Inuit Tapiriit Kanatami, Ottawa, Ontario, for both his insights and for managing this project.

The images that appear throughout the book have been reproduced herein with the permission of the following:

Dr. Ian Barker, Canadian Cooperative Wildlife Health Centre, OVC, University of Guelph, Guelph, Ontario: p. 78.

Kevin Burke, Parks Canada, Wapusk National Park, Churchill, Manitoba: p. 76.

- 
- Dr. G. Douglas Campbell, Canadian Cooperative Wildlife Health Centre, OVC, University of Guelph, Guelph, Ontario: pp. 33, 74.
- Dr. Marc Cattet, Canadian Cooperative Wildlife Health Centre, WCVN, University of Saskatchewan, Saskatoon, Saskatchewan: pp. 97, 101.
- Dr. Pierre-Yves Daoust, Canadian Cooperative Wildlife Health Centre, AVC, University of Prince Edward Island, Charlottetown, Prince Edward Island: pp. 20, 35, 36 bottom, 39.
- Dr. Bill Doidge, Nunavik Research Centre, Makivik Corporation, Kuujuaq, Quebec: p. 84.
- Dr. Pdraig Duignan, Cetacean Investigation Centre, Massey University, Palmerston North, New Zealand: p. 50.
- Dr. Greg Early, Marine Environmental Research Institute, Blue Hill, Maine: p. 44 bottom.
- Mats Forsberg, Arctic Pictures, Arctic Location, Skibotn, Norway: p. 79.
- Dr. Joe Geraci, National Aquarium in Baltimore, Baltimore, Maryland: pp. 13, 14, 16-18, 21, 28, 30, 34, 38, 40, 41 bottom, 42, 44 top, 46, 48, 52, 54, 56, 57, 62-67 top, 68-71 top, 87, 89, 90, 94, 100, photos on front cover, photos on back cover excluding bottom photo.
- Lois Harwood, MSc, Stock Assessment Biologist, Fisheries and Oceans Canada, Inuvik, Northwest Territories: p. 92 top.
- Dr. Brad Hicks, Taplow Feeds, North Vancouver, British Columbia: p. 15.
- Dr. Daniel Martineau, FMV, Universite de Montreal, St. Hyacinthe, Quebec: pp. 24, 25, 41 top, 53, 67 bottom, 91.
- Dr. Lena Measures, Fisheries and Oceans Canada,

Dr. David St. Aubin, Mystic Aquarium and Institute for
Exploration, Mystic, Connecticut: p. 72.

Dr. Ian Stirling, Canadian Wildlife Service, Edmonton,
Alberta: pp. 26, 32, 43, 96, 102.

D. White, Wildlife Officer, Department of Renewable
Resources, Nunavut: p. 22.

Dr. Oystein Wiig, Zoological Museum, University of Oslo,
Oslo, Norway: p. 98.

TABLE OF CONTENTS

1. Introduction	8
2. Collecting tissue samples for testing	11
3. Skin	
Sealpox	13
Seal lice	16
Whale “lice”	18
Hair loss	20
Pelt discolouration	22
Necrotizing dermatitis	24
Mange	26
Skin “craters”	28
Skin ulcers	30
Cysts	32
4. Blubber	
Parasitic cysts	34
Parasitic worms	36
5. Head and mouth	
Conjunctivitis	38
Abnormalities found in the mouth	40
Damaged or missing teeth	42
Parasites in the cranial sinuses	44
6. Heart	
Heartworm	46
7. Kidney	
Kidney stones	48
Parasites of the kidney	50

8. Lungs	
Pneumonia	52
Lungworms	54
9. Liver	
Liver abnormalities	56
Liver flukes	59
Vitamin A poisoning	61
10. Digestive tract	
Distended stomach	62
Stomach worms	64
Intestinal parasites	69
11. Lymph nodes and spleen	
Lymph nodes	72
Spleen	74
12. Zoonoses (Diseases transmissible to people)	
Rabies	76
Trichinellosis	78
Mycoplasma	81
Brucellosis	83
13. Miscellaneous conditions and systemic diseases	
Morbillivirus	85
Influenza	87
Emaciation	89
Injuries	94
Female pseudohermaphrodite polar bears	98
Abscesses	100
Tumours	102
Sources of further information	106

INTRODUCTION

PURPOSE OF THE GUIDE


The purpose of this guide is to provide information on the diseases, parasites, and abnormalities that may occur in marine mammals of the eastern Canadian Arctic. It also provides instructions on collection and submission of samples from animals that appear diseased or abnormal to laboratories for examination and testing.

It is hoped that the information provided in this guide will encourage greater sharing of knowledge and observations between hunters, biologists, and scientists who study wildlife disease, thereby improving our understanding of the health status of marine mammals in the Arctic. This guide contains information based on current knowledge of diseases in marine mammals, but it is recognized that there are huge gaps in this knowledge. As more samples are collected and examined, better scientific information will become available. While it is hoped that the guide will help answer questions, it should also serve as a first step in a process which will produce more and better information.

USE OF THE GUIDE

This guide attempts to describe parasites, abnormalities, and disease conditions that are known to occur in marine mammals commonly hunted and eaten in the eastern Canadian Arctic. Animals included are ringed seal, bearded seal, harp seal, walrus, beluga, narwhal, and polar bear. There is little or no information available on the diseases of some of these species - e.g. narwhal. Information has also been included on diseases that are known to occur in related species, such as harbour seals and dolphins, and on conditions that have been reported in the same species in other locations of their range - e.g. belugas in the St. Lawrence River. As well, there is some information on diseases such as morbillivirus, for which there is mainly serological evidence of its occurrence in the Arctic.

The material in this book is organized, for the most part, by body system, as this is the manner in which most abnormalities will be seen. There is also a section on conditions that can affect any part of the body (e.g. injuries) or conditions which may affect many parts (e.g. emaciation). Each section provides some basic information on the disease condition and gives instructions on what samples should be collected if laboratory examination of tissue is going to be done.



There is, as well, information in most sections on whether or not the condition represents a health risk to persons handling or eating parts of the carcass. It is difficult to give recommendations on the human use of these tissues. For example, thorough cooking will destroy many of the parasites and microbes that present hazards to humans and animals (e.g. sled dogs) who eat parts of marine mammals, but cooking may not be possible or culturally acceptable. The guide, however, does attempt to indicate where a risk may be present.

COLLECTING TISSUE SAMPLES FOR TESTING

What to sample?

1. If an animal has visible abnormalities:

At a minimum, collect a sample of the abnormal tissue and some normal tissue that borders it, for example a lump in the skin with some normal skin attached. If possible, send the entire tissue, for example the entire kidney, heart, or lung, rather than just a piece of it. Typically, the more tissue that can be examined, the more sense can be made of it.

2. If an animal is acting abnormally:

The brain is the organ that must be examined. If possible, the animal should be shot through the chest and not the head, keeping the brain as undamaged as possible. The simplest approach is to remove the entire head and submit it to the laboratory for removal and examination of the brain. Samples of other major organs (lung, liver, kidney, spleen, and heart) are also often useful.

3. If an animal is obviously sick:

A wide range of organs gives the best chance of finding out what the problem was. An ideal selection would include brain, heart, lung, liver, kidney, spleen or lymph nodes, and muscle.

What to do with samples that have been collected?

Samples should be placed in individual plastic bags (one organ per bag) if possible, and kept frozen until they are shipped. Ideally, a sample of each tissue should be collected and preserved in 10% formalin, in a ratio of 10 parts formalin to 1 part tissue. However, formalin is not widely available and is more difficult to ship. Freezing tissue is a method of preservation that is more widely available.

Hunters should submit samples, along with information on the species, age (young, juvenile or adult), sex, location, and a description of what is being submitted, to an agency or person (e.g. Regional Biologist, Resource Officer) who will ship it to the nearest laboratory.

Resource Officers or biologists can contact the CCWHC laboratory to which they can ship most directly and discuss the submission. Addresses, phone numbers and email addresses for CCWHC labs are listed at the back of the book.

SEALPOX



Sealpox. Firm lumps ranging from pinhead size to pea size or larger. (Dr. J. Geraci)

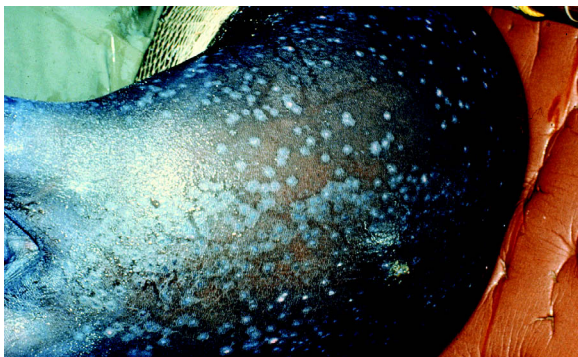
What is sealpox?

- ❖ Sealpox is a disease of the skin of seals and is caused by a virus.
- ❖ The virus is transmitted from one animal to another through rubbing, and occurs most commonly on the head and neck - areas which are most likely to come into contact with another animal.

What does sealpox look like?

- ❖ Sealpox produces small (2-3 cm) nodules or lumps in the skin which break open, ooze, and eventually heal, often leaving a greyish, slightly raised scar and an area without fur.
- ❖ These lumps may occur singly or in groups and are more common on the head and neck, although they may occur anywhere on the animal.

SEALPOX



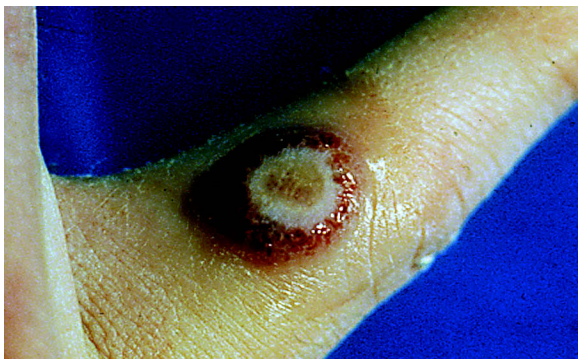Sealpox in a harp seal. Sealpox may occur anywhere on an animal's body. Animals are often otherwise healthy. (Dr. J. Geraci)

Species affected

- ❖ Sealpox has been reported in harbour seals, grey seals, northern fur seals, northern elephant seals, and California sea lions.
- ❖ It has not been reported in seals from the Canadian Arctic but it could appear here.

Human health concerns

- ❖ Humans who come into contact with sealpox can develop painful, swollen sores on their fingers (see photo, opposite page). These sores likely develop where seal pox has infected the skin through small open cuts or breaks in the skin.
- ❖ The sores will clear up on their own, although they may occur again.



Sealpox. (Dr. B. Hicks)

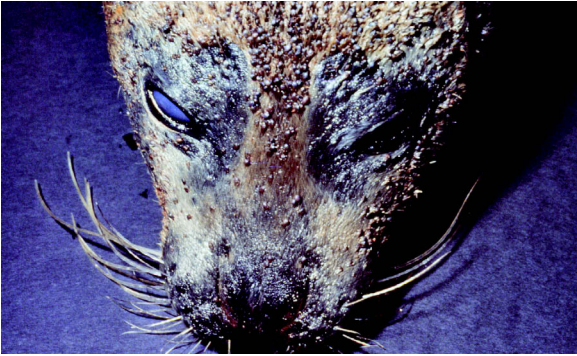
How to protect yourself

- ❖ You can avoid contact with the virus by not handling the pelt or skin of seals that have pox.
- ❖ You can reduce the chances of virus getting into your skin by washing your hands often or by wearing rubber gloves while handling the carcass of a seal that appears to have sealpox.

Samples to collect

- ❖ Collect pieces of skin containing one or more nodules, as well as a margin of normal tissue around the affected area.

SEAL LICE



Lice covering the head of a seal. Lice rarely occur in large numbers on healthy animals. (Dr. J. Geraci)

What are lice?

- ❖ Lice are small (1–5 mm), wingless insects that live on the skin. Their eggs, also called nits, are attached to hairs. Both eggs and adults are visible with the naked eye.
- ❖ The lice that occur on seals are sucking lice, which use sharp mouthparts to penetrate the skin of the host and suck blood and tissue fluids.
- ❖ Lice are transmitted from one animal to another through close contact while the animals are out of the water.

Species affected

- ❖ Lice are commonly reported on harbour seals, grey seals, harp seals, ringed seals, and other species of phocids (true seals).



Close-up of a seal louse (*Echinophthirius horridus*). (Dr. J. Geraci)

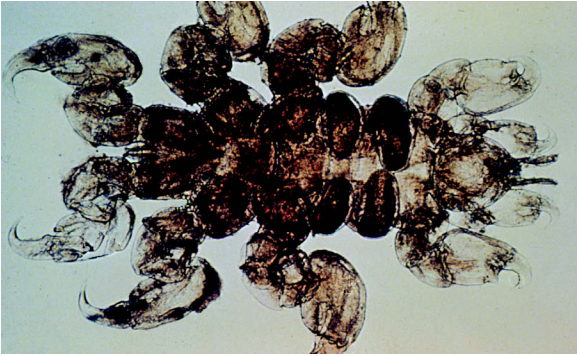Effects on the host

- ❖ Lice may irritate the host and in the case of heavy infestations may cause loss of tissue fluid and blood, leading to anemia.
- ❖ The sucking louse of harbour seals acts as the intermediate host for the heartworm (*Acanthocheilonema spirocauda*) which affects this species of seal (see p. 46).
- ❖ Large numbers of lice are more likely to occur in animals that are sick or weak and are spending more time than normal out of the water.

Human health concerns

- ❖ Lice tend to be very host-specific and are not transmitted easily to other species. Seal lice will not feed on people.

WHALE LICE



Whale louse. They are considered harmless to the affected animal and are not known to be transmissible to terrestrial species. (Dr. J. Geraci)

What are whale “lice”?

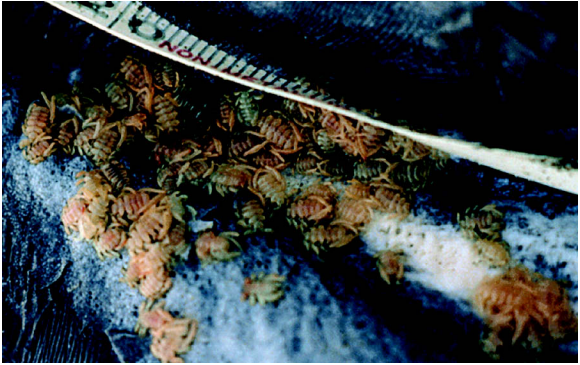- ❖ Whale lice are not really lice, but are actually small crustaceans (amphipods) that look and behave somewhat like lice.
- ❖ Whale lice live in cracks in the skin and on barnacles and bumps on the skin of whales.

Species affected

- ❖ Both toothed whales (e.g. beluga) and baleen whales (e.g. right whale) can harbour these parasites.

Effects on the host species

- ❖ Whale lice do not cause disease in their host species. Large numbers of lice indicate an unhealthy animal.



Whale lice may be found in fissures and crevices and on protuberances on the surface of large whales. (Dr. L. Measures)

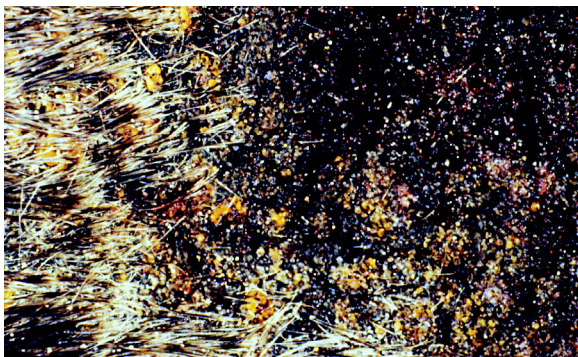
Whale lice found in the crevices and protected areas between barnacles. (Dr. L. Measures)



Human health concerns

- ❖ None

HAIR LOSS



Dermatitis-associated hair loss and fungal growth in an immature harp seal. The hair loss may result from abnormal moulting. Fungi may grow excessively on abnormal skin surfaces. (Dr. P-Y Daoust)

Hair loss

- ❖ Seals may be seen with extensive areas of hair loss. This change may be restricted to a small area or may involve the entire body.

Animals affected

- ❖ Abnormal hair loss has been described in seals. It may affect newborn pups, which may be born (sometimes stillborn), without hair. It may also be seen in older seals, in which hair loss is more likely to be patchy in distribution.

Cause of Hair Loss

- ❖ In newborn pups, the absence of hair is most likely to

be either a genetic problem or the result of some event during pregnancy. In an older animal, it may be the result of an abnormal moult, possibly accompanied by an opportunistic bacterial or fungal skin infection. Moult, the process by which mammals shed their fur or outer layer of skin and replace it with new fur or skin, occurs annually in seals and in some whales (e.g. beluga). The process may be interrupted or impaired by factors such as disease, poor nutrition, and stress. If an animal does not successfully moult, the resulting abnormal skin will become a target for invasion by bacteria and fungi, which may cause further damage to both skin and existing hair.

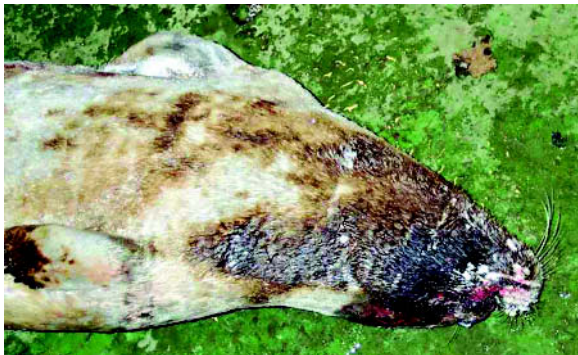Samples to collect

- ❖ In any case of abnormal hairlessness, a sample of skin, including both affected and more normal appearing skin, is critical. Thyroid and adrenals are needed to properly evaluate the condition. Samples of other major organs, such as heart, lung, liver, kidney, and spleen are also useful.



Hairless stillborn harp seal. (Dr. J. Geraci)

PELT DISCOLOURATION



Ringed seal with fungal infection. (D. White)

The appearance of discoloured skin

- ❖ Occasionally, seals have been seen with areas of skin that are darker than normal and with loss of hair in these areas. Affected areas may appear reddened, and are characterized by broken hair shafts and marked thickening and flaking of the skin.

The cause of skin discolouration

- ❖ Initially, it was thought that the seals may have encountered an oil spill which damaged and stained their pelts. However, the lesion appears to be caused by a fungus infecting the skin and hair shafts. The fungus has not yet been identified.

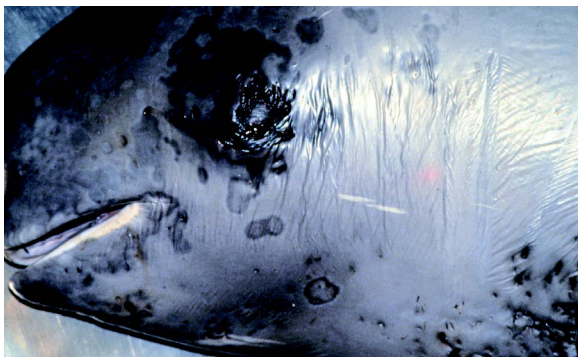Effects on the animal

- ❖ This infection can cause significant hair loss.

Samples to collect

- ❖ A full thickness sample of skin from fur to the blubber layer, including both affected and unaffected areas, is the critical sample. If the animal appears to be suffering from a more generalized illness, a sample of the major tissues (heart, lung, liver, spleen, kidney, and brain, if possible) should also be collected.

NECROTIZING DERMATITIS



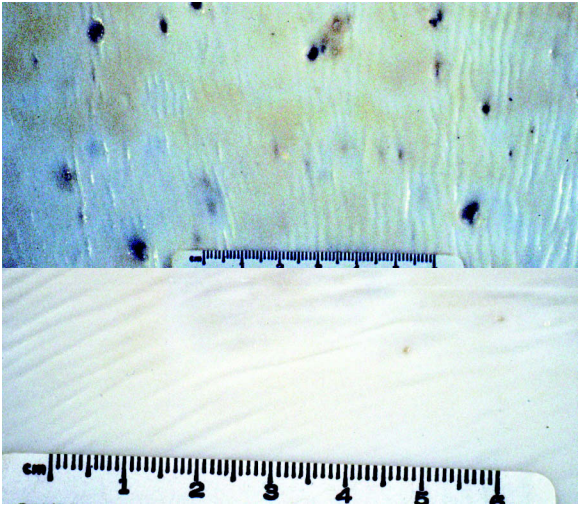
Beluga from the St. Lawrence River with necrotizing dermatitis. (Dr. D. Martineau)

What is necrotizing dermatitis?

- ❖ Necrotizing dermatitis is a severe skin disease characterized by cell death and peeling of the skin.
- ❖ There may be many different causes, including an immune mediated response to disease or physical trauma to the skin - the exact cause is unknown.

What does necrotizing dermatitis look like?

- ❖ The skin may be dry and peeling, and large patches may be discoloured due to localized cell death.
- ❖ Affected areas of the skin may have multiple, random, variably-sized, raised, pale grey areas which eventually rupture and are slow to heal.



Necrotizing dermatitis in a beluga. (Dr. D. Martineau)

What animals get necrotizing dermatitis?

- ❖ This condition has been seen in St. Lawrence belugas. It has not been described in belugas from other locations.

Samples to collect

- ❖ Collect portions of the affected tissues.

MANGE



Mange in a polar bear. (Dr. I. Stirling)

What is mange?

- ❖ Mange is a general term for skin disease caused by mites, which are microscopic parasites related to spiders (arachnids). There are many different species of mites, each of which tends to occur on a different host species.
- ❖ Sarcoptic mange is a disease caused by a mite that tunnels in the skin of the host, causing a great deal of irritation. Affected animals are likely to be very itchy. The mite is transmitted from animal to animal through close contact.

Species affected

- ❖ Mange is most likely to occur in polar bears.

What does mange look like?

- ❖ The animal will be itchy and the skin will look thickened and cracked. Severely affected animals will become weak and thin.
- ❖ There is likely to be hair loss with thickening and crusting of the skin. Affected areas are likely to be rubbed or scratched by the infected animal, and may break open and become infected with bacteria.
- ❖ Tips of ears, elbows, lower legs and face are areas that may become infected.

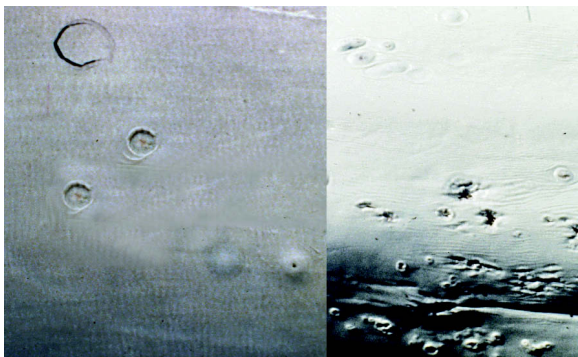
Human health concerns

- ❖ Mites that cause mange can be transmitted to humans and dogs, but are unlikely to establish infections. The mites cannot complete their life cycle on these hosts and will eventually die out. There may be a brief period (days to weeks) in which the affected area(s) will be itchy.

Samples to collect

- ❖ Mange can be confirmed from a skin sample of the affected area. A skin sample of both normal and affected skin is most useful.

SKIN “CRATERS”



Skin “craters” in two belugas. Crater lesions are not associated with a general illness. (Dr. J. Geraci)

What is a “skin crater”?

- ❖ Skin craters are localized changes in the skin. A skin crater may take the form of a circular area that appears depressed and has a thin margin raised above the depression (photo on left), or it may be mostly raised with a small depression in the centre (photo on right). These two forms may represent different stages of the same lesion. Skin craters may be as much as a few centimetres in diameter.

Species affected

- ❖ Skin craters have been seen in belugas.

Cause of “skin craters”?

- ❖ Their cause is not known. Their appearance suggests that they may be caused by a virus.

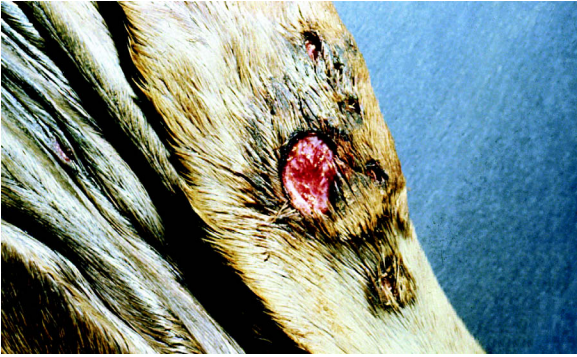
Human health concerns

- ❖ There is no known risk to human health. However, to be cautious, the skin and underlying blubber from areas with craters should not be eaten.

Samples to collect

- ❖ Collect a piece of skin and underlying blubber that contains both craters and surrounding normal tissue.

SKIN ULCERS



Skin ulcers on the flippers are often found in debilitated individuals. (Dr. J. Geraci)

What is an ulcer?

- ❖ An ulcer is an open sore in the skin, caused by the death of the outermost cells of the skin. Death of the cells results in exposure of the underlying tissue, leaving it without its normal protective covering.
- ❖ Ulcers may result from many causes: trauma, stress, burns (thermal or chemical) or viruses. They may become contaminated with bacteria, which may spread from there through the blood to other tissues.

What do ulcers look like?

- ❖ Ulcers are raw, open sores which may be red and may ooze blood, clear tissue fluid, or pus.
- ❖ As they heal, skin grows from the margins inward and may appear puckered.

- ❖ They will appear depressed in comparison to the surrounding normal tissue.

Species affected

- ❖ Any species of marine mammal could develop ulcers.

Effects on the animal

- ❖ Ulcers may develop over pressure points where bones lie right beneath the skin and where the skin is more easily rubbed and abraded.
- ❖ An ulcer by itself will be uncomfortable but will have no serious effects unless it becomes colonized by bacteria that spread to other tissues.
- ❖ Ulcers may be a sign that the animal is not well and is spending too much time out of the water.

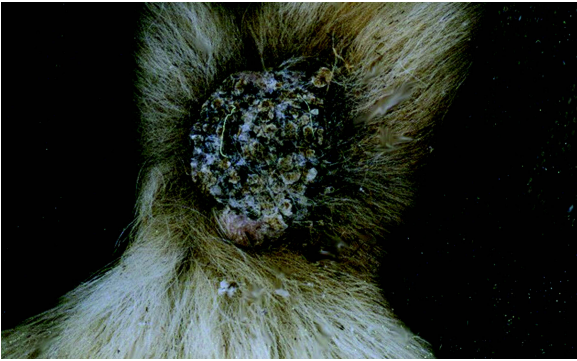Human health concerns

- ❖ Areas with ulcers should be cut out and not consumed.
- ❖ Since it is possible that the animal is sick in other ways, special care should be taken to inspect the carcass thoroughly for other signs of disease.

Samples to collect

- ❖ Cut out the ulcer and a surrounding margin of normal tissue.
- ❖ Since an animal with ulcers may be sick, samples of major organs (heart, lung, liver, kidney, and spleen) may be useful for examination.

CYSTS



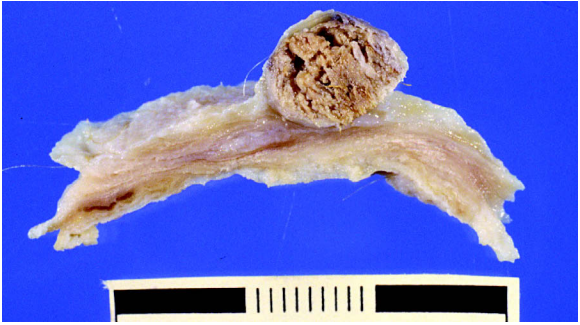
Cyst in the skin of a polar bear. (Dr. I. Stirling)

What is a cyst?

- ❖ A cyst is a closed cavity or sac filled with air, fluid, pus, or other material. Some cysts are considered 'normal' and are not indicative of a diseased state.
- ❖ A cyst is also a stage in the life cycle of some parasites during which they are enclosed within a protective wall. Not all cysts contain parasites.
- ❖ Animals may appear otherwise normal and healthy.
- ❖ Cysts can be found inside or outside the body.

What animals get cysts?

- ❖ Any species of animal can develop cysts.

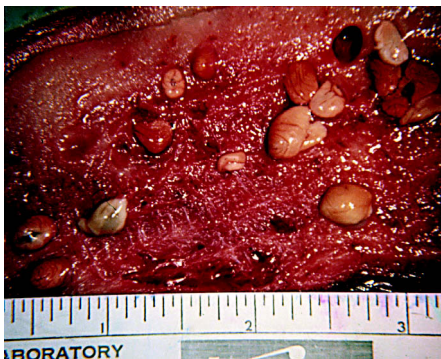

Cyst, approximately 1 cm in diameter, from the skin of a polar bear. (Dr. D. Campbell)

Samples to collect

- ❖ Collect the cyst and the surrounding tissue.

PARASITIC CYSTS



Larval cysts of the parasitic worm *Phyllobothrium delphini* in an Atlantic white-sided dolphin. (Dr. J. Geraci)

What are parasitic cysts?

- ❖ Parasitic cysts are approximately 5-7 mm in diameter, and are found in the blubber. They contain fluid and the intermediate stage of a tapeworm. The adult tapeworm is found in the intestines of the final host, which is likely a shark. The shark becomes infected by eating the cysts in the blubber of infected marine mammals.
- ❖ Cysts can occur anywhere in the blubber, but are most common in the abdominal region, which may help in their transfer to sharks, as sharks generally attack whales from below.

Species affected

- ❖ Whales and dolphins; parasitic cysts are rarely found in seals.

Effects on the host

- ❖ none

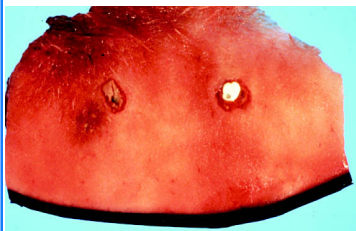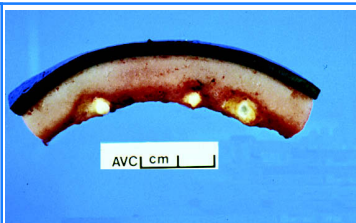
Human health concerns

- ❖ Humans are likely incapable of acting as final hosts for this tapeworm. To be cautious, avoid eating cysts.

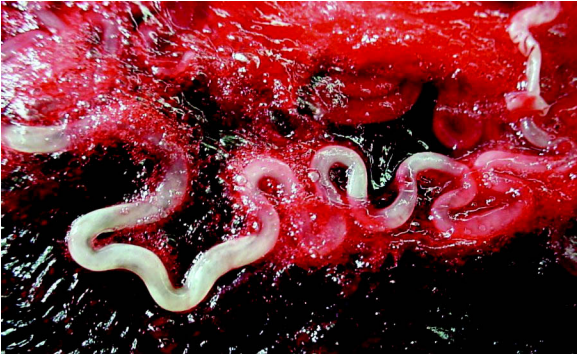Samples to collect

- ❖ Collect a piece of blubber containing some intact cysts that have not been broken open.

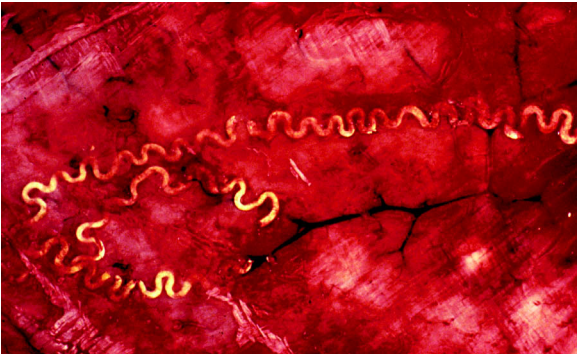
Developmental stage of a tapeworm (likely a *Phyllobothrium* species) in the deep region of the blubber of a white-sided dolphin (above) and in the blubber of a pilot whale. (Dr. P-Y Daoust)



PARASITIC WORMS



Crassicauda roundworm in the fascia underlying the blubber in a white-sided dolphin. (Dr. L. Measures)



Mineralized parasite (likely *Crassicauda*) in the fascia underlying the blubber of a white-sided dolphin. (Dr. P-Y Daoust)

Parasitic worms in the blubber

- ❖ Several species of roundworm (nematode) parasites may be found in the connective tissue between the blubber and muscle.

Species affected

- ❖ Seals, toothed and baleen whales, and dolphins.
- ❖ Seals and whales are hosts to different species of worms.

Effects on host species

- ❖ The parasites are harmless when located in the blubber.
- ❖ Some species may also be found in other locations, such as the mammary glands and sinuses of the head (e.g. *Crassicauda* sp.), or the heart (e.g. *Acanthocheilonema* sp.) where they may cause significant disease.

Human health concerns

- ❖ None.

Samples to collect

- ❖ Collect a sample of the affected area containing one or more entire, intact worms. As these worms are often large and sinuous (snake-like) it is best to cut the connective tissue containing the worms.

CONJUNCTIVITIS



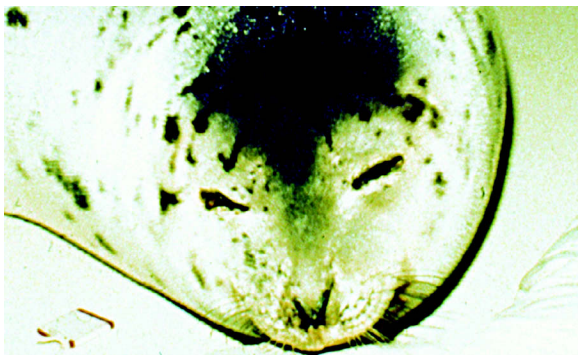
Eye infection in a seal with influenza. (Dr. J. Geraci)

What is conjunctivitis?

- ❖ Conjunctivitis is an inflammation of the lining of the eyelids. In affected animals, the eyes may appear to be slightly cloudy and partly shut, and there may be a discharge that accumulates in the corners of the eye.

What causes conjunctivitis?

- ❖ It can be caused by viruses (see Influenza and Morbillivirus) or bacteria. It can be a localized infection, like pinkeye in humans, or it can be part of a more generalized, systemic disease such as Morbillivirus (distemper) or Influenza.



Harp seal with distemper. Note the encrusted eyelids, suggesting inflammation of the tissues in contact with the eye. (Dr. P-Y Daoust)

Other things to look for

- ❖ Animals that have conjunctivitis as part of a more generalized infection are likely to show inflammation of the trachea (windpipe) or lungs (see Pneumonia).

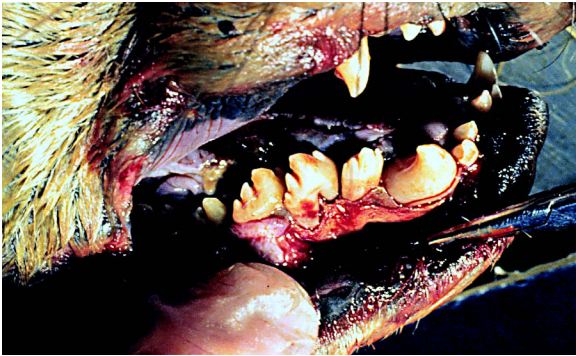
Human health concerns

- ❖ Animals showing signs of systemic disease, such as pneumonia, should not be eaten.

Samples to collect

- ❖ Collect the entire head or eyelids only; lungs if there is evidence of pneumonia; other filtering organs (liver, spleen, kidney) if there is evidence of generalized illness.

ABNORMALITIES FOUND IN THE MOUTH



Erosion of the gums is a degenerative process that occurs in severely malnourished and very old animals. (Dr. J. Geraci)

Common conditions

- ❖ Gum tissue around teeth may be lost, causing teeth to become more prominent and loose in their sockets.
- ❖ Gums may become inflamed (gingivitis).
- ❖ Ulcers may occur in the roof of the mouth.

Species affected

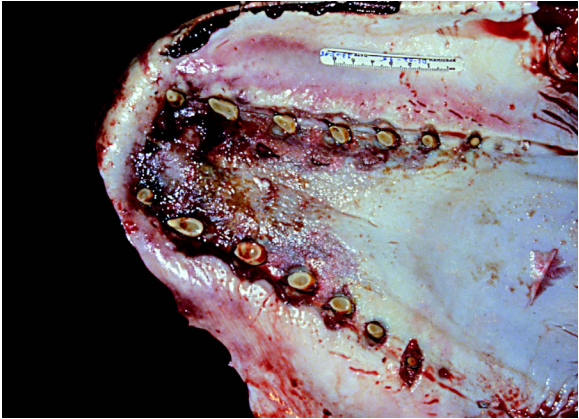
- ❖ Any species of marine mammal can be affected.

Importance of abnormalities of the mouth

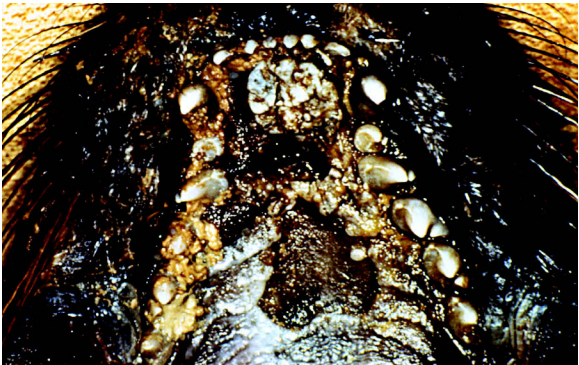
- ❖ These abnormalities occur most commonly in animals that are malnourished (see Emaciation).
- ❖ They may also be a sign of serious disease; there may be abnormalities in other organs.

Human health concerns

- ❖ The safety of the meat can only be judged by looking at the whole animal - its body condition, the presence or absence of other abnormalities, and the appearance of the meat.

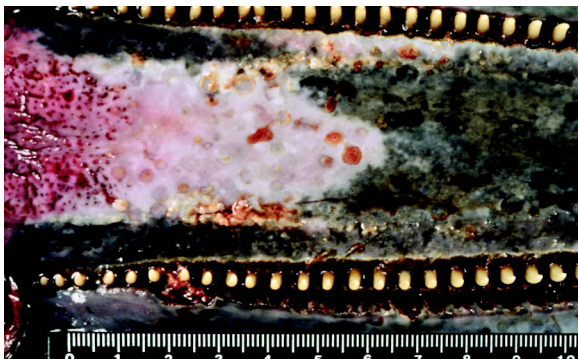


Gingivitis in a beluga whale. (Dr. D. Martineau)



Ulcers in the mouth of a seal. A mouth in this condition is indicative of an animal that is weak and malnourished. (Dr. J. Geraci)

DAMAGED/ MISSING TEETH



Mouth wounds and missing teeth. (Dr. J. Geraci)

Broken or missing teeth

- ❖ Damaged or missing teeth are not uncommon. Damaged teeth may be worn down from the effects of years of wear, or they may be broken off as the result of injury.

What is the effect on the animal?

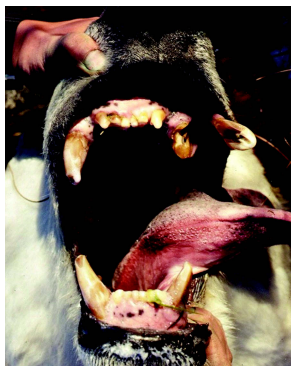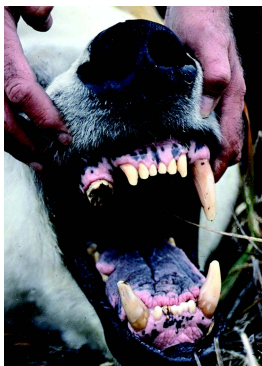- ❖ Worn or missing teeth may cause difficulty in holding, biting or chewing food, resulting in poor body condition. Broken or worn teeth may act as a point of entry for bacteria, leading to infections of the bones of the jaws. This will cause even more serious problems in handling and eating food, and could lead to disease affecting many parts of the body.

Human health concerns

- ❖ Risks to humans from eating the meat of animals with damaged teeth should be judged on the appearance of the whole animal. If the only abnormalities seen are in the teeth and there is no evidence of disease in other parts of the body, the meat should be safe to eat. If the animal appears emaciated and unhealthy (see Emaciation) the carcass may be unsuitable for consumption.

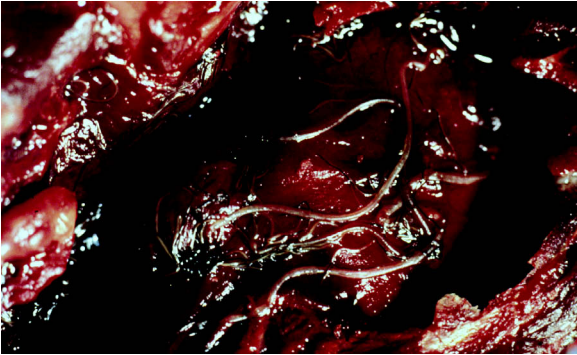
Samples to collect for further diagnosis

- ❖ If the animal appears otherwise healthy, the entire head or a jaw with infected teeth could be collected. If the animal appears to be ill, a selection of other tissues (e.g. heart, lung, liver, spleen, and kidney) should also be submitted.

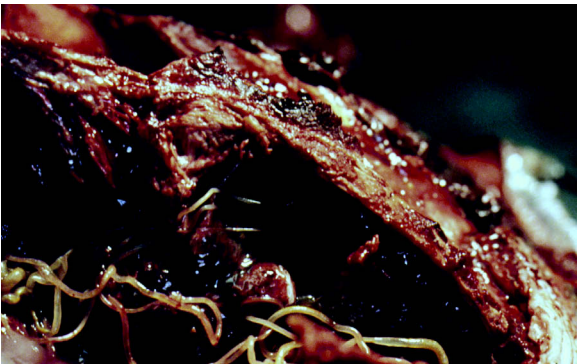

Male polar bear with broken tooth. (Dr. I. Stirling)

PARASITES IN THE CRANIAL SINUSES



Nematodes in the cranial sinuses of a cetacean. A similar condition can be found in belugas and narwhals with parasites located anywhere within the external auditory system (middle ear, ear canal, head or cranial sinuses). (*Crassicauda* and *Stenurus*). (Dr. J. Geraci)



Crassicauda in the head. (Dr. G. Early)

What are the nasal sinuses?

- ❖ Nasal sinuses are large, air-filled cavities, lined with mucous membranes and found within the nasal bones.

What parasites occur there?

- ❖ Parasites that occur there may be either trematodes (flukes) or nematodes (roundworms). Flukes are small (usually a few mm long) and flat, while roundworms are cylindrical, elongate, and often more robust. These parasites may occur in the nasal and cranial or head sinuses as well as in the ear canal and middle ear.

Species affected

- ❖ Toothed whales (including belugas and narwhals) may be infected by flukes in the nasal sinuses (*Nasitrema* sp.) or by roundworms (*Crassicauda* sp. and *Stenurus* sp.) in the cranial sinuses.

Effects on the host

- ❖ It is controversial whether or not the presence of these parasites affects the host. Flukes may, on occasion, migrate to the brain causing severe damage. Roundworms can cause erosion of the bones of the skull. It has been speculated that some of these parasites may affect the animals' echolocation and cause them to come ashore in mass strandings.

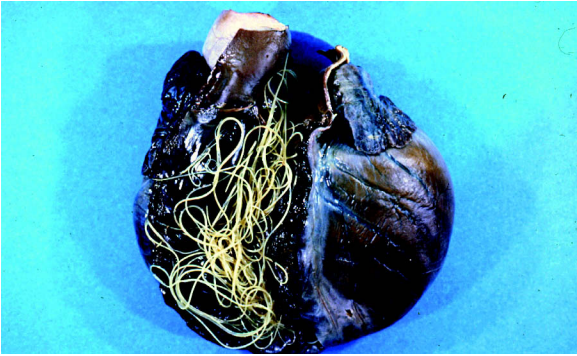
Human health concerns

- ❖ None

Samples to collect

- ❖ Entire head if it is available.
- ❖ Worms for identification if the head is not collected intact.

HEARTWORM



Heartworm. The heart of a harbour seal, opened to expose the nematode *Acanthocheilonema*. (Dr. J. Geraci)

What is heartworm?

- ❖ Heartworms are nematode (roundworm) parasites found in the right ventricle of the heart and arteries supplying the lungs of seals. Their scientific name is *Acanthocheilonema*. Adult worms produce small larval offspring (microfilaria) which travel in the bloodstream where they are picked up by the intermediate host, the seal louse, which feeds on the blood of seals (see Lice). They are transmitted to other seals through the bite of an infected louse, which can move from seal to seal during close contact (e.g. mother to pup)

Species affected

- ❖ Heartworm occurs in harbour, harp, ringed, and hooded seals. It has not been found in grey or bearded seals.

Effects on the host species

- ❖ The worms can cause damage to the heart, arteries, and lungs.

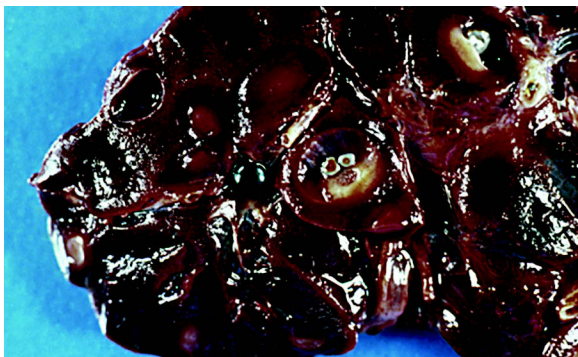
Human health concerns

- ❖ None. The worms are not transmissible to people.

Samples to collect

- ❖ The entire heart with worms, along with samples of the lungs is ideal.
- ❖ Samples of entire, intact worms may be used for identification of the species involved.

KIDNEY STONES



Kidney stones in a ringed seal from the Canadian Arctic.
(Dr. J. Geraci)

What are kidney stones?

- ❖ The main job of the kidneys is to remove waste from the blood and return the cleaned blood back to the body. The waste leaves the body in the urine.
- ❖ A kidney stone develops when certain chemicals in the urine form crystals that stick together, making a hard stone.
- ❖ Most stones are formed in the kidney, but they can form anywhere along the urinary tract.
- ❖ Some stones stay in the kidney, others travel down the urinary tract.
- ❖ Large stones might block the flow of urine causing waste and pressure to build up in the kidneys. This can result in serious kidney damage.

What do kidney stones look like?

- ❖ The crystals that stick together may grow into a kidney stone ranging in size from a tiny grain of sand to a golf ball.
- ❖ Kidney stones may be smooth or jagged, and may vary in shape. Most kidney stones are yellow or brown, but variations in chemical composition can produce stones that are tan, gold, or black.

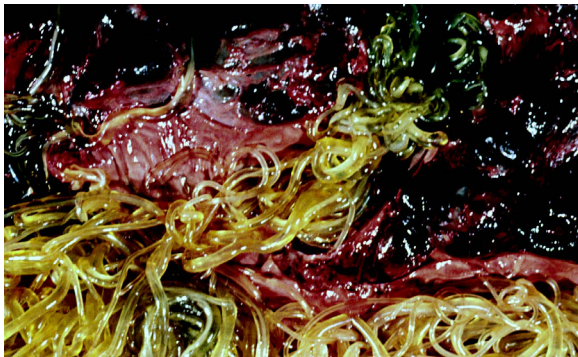
Species affected

- ❖ All marine mammals can be affected.

Human health concerns

- ❖ Meat from an animal with kidney stones is suitable for consumption, provided no additional disease or illness is present.

PARASITES OF THE KIDNEY



Crassicauda sp. in the kidney of a whale. These parasites are found nested in large numbers in the vessels of the kidney in many species including beluga and bowhead whales. They cause severe damage to the kidney, which can affect the health of the animal. (Dr. P. Duignan)

Parasites of the kidney

- ❖ *Crassicauda* are large nematodes (roundworms) found in the kidneys of whales. These worms embed their heads into the tissue of the affected organ, leaving their tail end free to shed eggs into the environment, in this case through the urinary tract.

Species affected

- ❖ They occur in both toothed and baleen whales.

Effects on host species

- ❖ The worms cause the formation of fibrous structures that invade and ultimately block the blood vessels leading into and out of the kidney. This can result in serious damage to the kidney. It is thought that parasites of the kidney may play a role in causing the death of some animals.

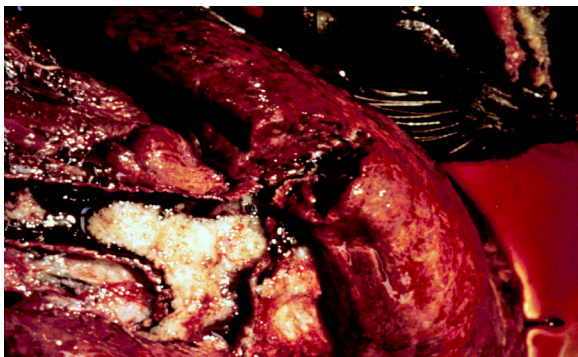
Human health concerns

- ❖ None.

Samples to collect

- ❖ The ideal sample is an affected kidney and the blood vessels going into and out of it. A second choice sample would be the worms themselves.

PNEUMONIA



Pneumonia. Froth in the airways. (Dr. J. Geraci)

What is pneumonia?

- ❖ Pneumonia is a disease condition in which there is inflammation of the tissue of the lung. The small and large airways that deliver air into the lung may also be involved.

What causes pneumonia?

- ❖ Pneumonia may be due to many causes, including viruses (see Morbillivirus, Influenza), bacteria (e.g. Mycoplasma), parasites (see Lungworm), fungus, or some combination of these agents. For example, an animal with influenza would become more vulnerable to secondary infection with bacteria, such as Mycoplasma sp., and this combination of two agents will be much more dangerous than either one alone. Heavy burdens of parasites may cause partial blockage of the airways and a mixture of parasite eggs, mucus and bacteria may end up deeper in the lung where they

will cause inflammation and perhaps the formation of abscesses (see Abscesses).

What does pneumonia look like?

- ❖ A normal lung is pale pink in colour, light, and air-filled in texture. Animals that have been shot will often have patchy areas of hemorrhage scattered throughout the lung. The lungs of an animal with pneumonia will have areas that are darker and firmer than normal. The location of these changes will vary with the cause of the pneumonia, but in many instances will follow the major airways into the lung. The affected areas may be firm, even solid, and without air, and there may be leakage of tissue fluids and other substances onto the outer surface of the lungs. Lungs with abscesses will have individual nodules of inflammation that may be widely scattered.

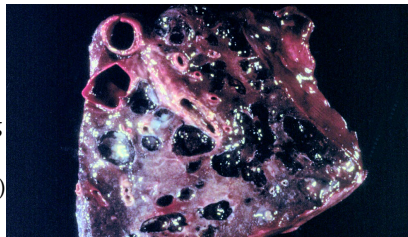
How pneumonia is diagnosed

- ❖ Pneumonia is diagnosed by gross and microscopic examination of an affected lung and, most importantly, by identification of the agents involved.

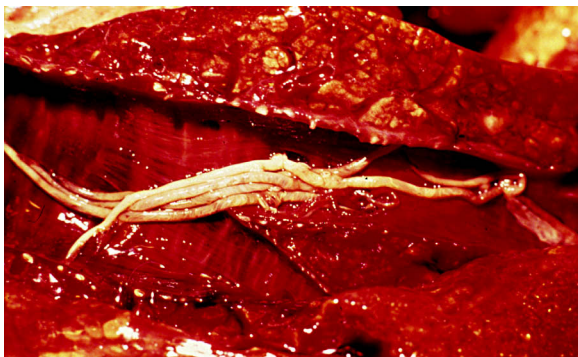Samples to collect

- ❖ Collect a sample of the lung, including both affected and normal tissue. Samples of other organs, such as liver, kidney, spleen, lymph node, and heart may also be useful.

Lung of a beluga with pneumonia. Note that the lung is red and wet. (Dr. D. Martineau)



LUNGWORMS



Lungworms (*Otostrongylus circumlitus*) in the airways of ringed seals. (Dr. J. Geraci)

What are lungworms?

- ❖ Lungworms are parasitic round worms that may be found in the lungs and airways of their hosts.
- ❖ Lungworms occurring in seals are different from those occurring in dolphins and whales.
- ❖ *Otostrongylus* species are common in young seals.
- ❖ Many different species of lungworms can occur in dolphins and whales.

What do lungworms look like?

- ❖ Lungworms are white, threadlike worms usually less than 7 cm in length.
- ❖ Worms and/or small round grey lumps of dead tissue up to 2 cm in diameter may be found in the lungs when butchering.

- ❖ Animals with severe lungworm infection may have difficulty breathing and may cough, especially after periods of intense activity.
- ❖ Affected animals may be weak, thin, and have matted, dull hair.

Species affected

- ❖ Seals and whales.
- ❖ Many young seals may have lungworms.
- ❖ Lungworms are associated with pneumonia in free-ranging ringed seals in the Canadian Arctic.

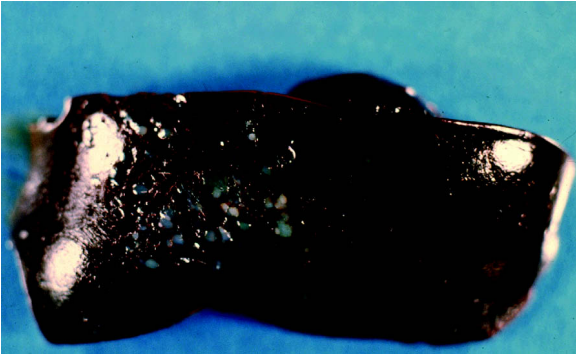
Human health concerns

- ❖ Meat from animals with a lungworm infection is still suitable for eating.

Samples to collect

- ❖ Collect samples of the affected lung including the worms.
- ❖ The worms alone may be submitted if it is not possible to collect the lung.

LIVER ABNORMALITIES




Small white plaques on the surface of the liver of a ringed seal from the western Canadian Arctic. These plaques are scars that probably represent migration tracks of larval nematodes, perhaps lungworms. (Dr. J. Geraci)

Plaques and white spots on the liver

- ❖ The liver plays many important roles in maintaining health and normal body function and is subject to many insults, which may result in physical changes that can be seen with the naked eye. These include plaques (flat, whitish areas on the surface of the liver) and spots (usually pale yellow to white, scattered throughout the tissue). They can vary greatly in size.

What causes these conditions?

- ❖ Abnormalities in the liver may be due to many causes. Migrating parasites are a common cause of plaques and tiny spots. Bacteria and viruses may cause spots, which are areas in which there is cell death and/or



Spots and scars on the surface of the liver of a ringed seal from the western Canadian Arctic. This may be the early stages of a roundworm parasitic migration. (Dr. J. Geraci)

inflammation. Tumours may also appear as solid areas within the liver.

Significance to the animal

- ❖ Some of these lesions are of no great importance. Many animals have plaque-like scars due to immature migrating parasitic stages but the greater effect on health is due to adult parasites wherever they finally reside (e.g. kidneys, lungs, heart). White spots scattered throughout the liver are usually evidence of a serious disease which may have caused illness or the death of the affected animal.

LIVER ABNORMALITIES

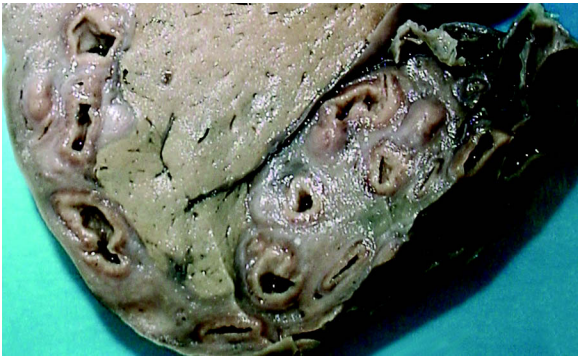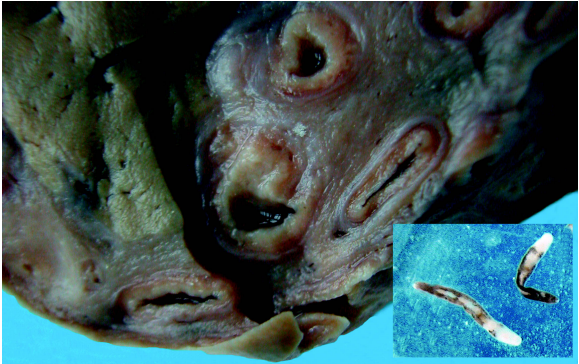Human health concerns

- ❖ White spots in the liver may be evidence of systemic bacterial or viral disease.
- ❖ Tissues from these animals should not be eaten.

Samples to collect for testing

- ❖ Collect affected areas of the liver.
- ❖ Spleen, lung, and kidney are also useful samples for examination.

LIVER FLUKES



Liver flukes (*Orthosplanchnus arcticus*) in a ringed seal. (Dr. L. Measures)

Species of parasite involved

- ❖ Several different species of flukes (trematodes) are found in the bile ducts, pancreatic ducts, and surrounding tissue of marine mammals.

LIVER FLUKES

Species affected

- ❖ Probably all marine mammals are susceptible to flukes.
- ❖ Infection has been reported as extremely common in harbour porpoises on the east coast of the USA and flukes have also been reported in a bearded seal off the coast of Alaska.
- ❖ In general, there is little information available on their occurrence in marine mammals in the Arctic.

Effects on the host species

- ❖ The parasites may cause inflammation and fibrosis of the bile duct and pancreatic duct, with spread of this process into the surrounding liver and pancreas. If this change is pronounced, the function of these organs may be affected.
- ❖ This could be a factor in the poor body condition or death of some affected animals.

Samples to collect

- ❖ Collect the liver and pancreas.
- ❖ Parasites may also be collected and preserved in alcohol.

VITAMIN A POISONING

Vitamin A Poisoning

- ❖ The livers of polar bears and bearded seals contain high levels of Vitamin A. Humans require this vitamin in small amounts but large amounts are toxic and can cause serious disease. Many body systems and organs, including skin, liver, bone, and brain, can be affected by poisoning with excess Vitamin A. This condition can cause death in humans and dogs. For this reason, liver from polar bears and bearded seals should not be eaten by humans and should not be fed to dogs.

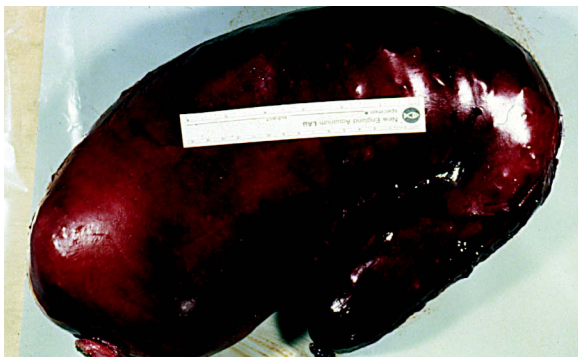What does the liver look like?

- ❖ Polar bears and bearded seals have naturally high concentrations of Vitamin A in their livers. This is not a diseased state.
- ❖ Polar bear or bearded seal liver with high levels of Vitamin A appears entirely normal, with no outwardly visible sign that there is something wrong with it. All livers from these species should be considered toxic.

How to protect yourself

- ❖ Do not eat liver from polar bears or bearded seals and do not feed it to dogs. Even a small amount could cause serious illness and even death.
- ❖ The remainder of the carcass is safe to eat.

DISTENDED STOMACH



Abnormally distended (stretched) stomach of a hooded seal.
(Dr. J. Geraci)

Foreign objects in the stomach

- ❖ Animals may be found with foreign objects in their stomachs. These are items that would not normally be food for the animal and usually are not digestible. Rocks are a common example.

Species affected

- ❖ Any species of marine mammal could develop this problem, but it is most likely to occur in seals and walruses.

Effects on the animal

- ❖ The stomach may appear greatly distended (enlarged). This can happen with a large meal of normal food as well, but in that case the pressure of the distention will be relieved as the food is digested and passes along the



The distended stomach of the hooded seal (previous page) opened to reveal a large quantity of stones. (Dr. J. Geraci)

digestive tract. In the case of foreign objects, the distention will not be relieved and the pressure will cause discomfort.

- ❖ The presence of foreign objects in the stomach may be related to an abnormal appetite or to lack of normal food and may be an indication that an animal is sick or weak. Animals with large amounts of foreign material in their stomachs should be closely examined for other evidence of serious disease.

Human health concerns

- ❖ These animals are likely sick or in poor body condition and are probably not desirable to eat. If the animal shows obvious signs of other illness it should not be eaten.

Samples to collect

- ❖ Collect the entire stomach and its contents, as well as a sample of the major organs including the heart, lung, liver, kidney, and spleen.

STOMACH WORMS



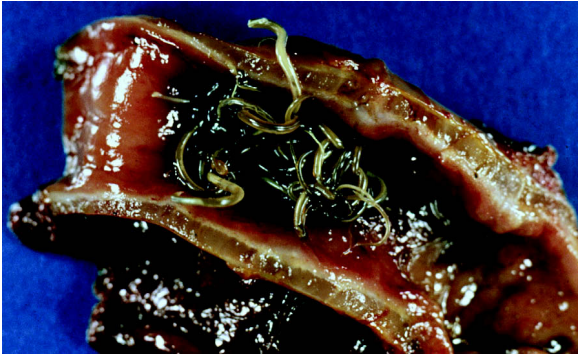
Numerous roundworms (likely *Contracaecum* species) attached to the stomach lining of an immature harp seal. (Dr. J. Geraci)

What are stomach worms?

- ❖ Stomach worms are nematodes (roundworms) whose adult stage is found in the stomachs of seals.
- ❖ Immature stages of these worms are found in fish, such as cod or plaice, which are intermediate hosts.
- ❖ These immature stages are transmitted to seals when infected fish are eaten. The immature worms mature to adults and complete their life cycle in the seals.

Species affected?

- ❖ Any species of marine mammal is susceptible.



Roundworms in the pylorus of a ringed seal from the western Canadian Arctic. Worms are normally found in the stomach. In this case, however, they were just beyond the sphincter, burrowed deeply into the mucosa, and caused ulcerations. (Dr. J. Geraci)

What are the effects on the seals?

- ❖ Worms may cause local irritation, which, if severe, can lead to ulcers or gastric perforations.

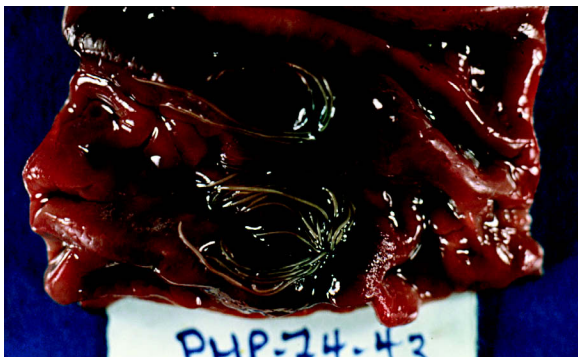Human health concerns

- ❖ No direct concerns.

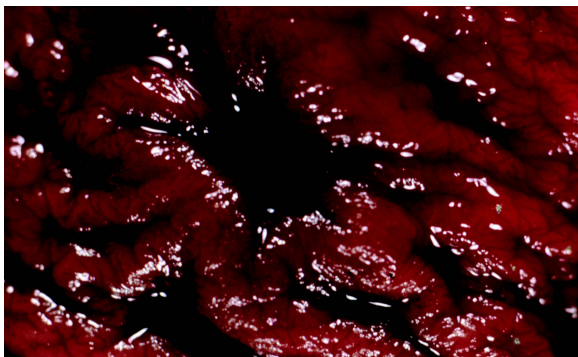
Samples to collect

- ❖ Collect the entire stomach or the affected portions of the stomach with worms. As a second choice, the worms themselves may be collected without a sample of the stomach, and stored in alcohol.

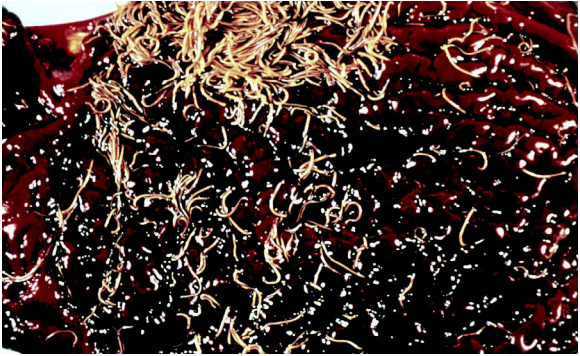
STOMACH WORMS



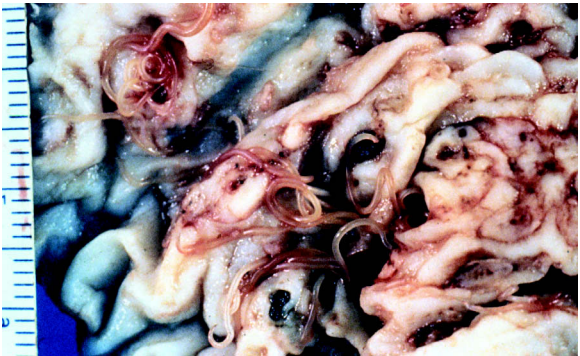Worms with heads deeply embedded in the stomach wall causing ulceration in the stomach of a ringed seal from the western Canadian Arctic. (Dr. J. Geraci)



Gastric ulcer in the stomach of a ringed seal after nematodes were removed. (Dr. J. Geraci)

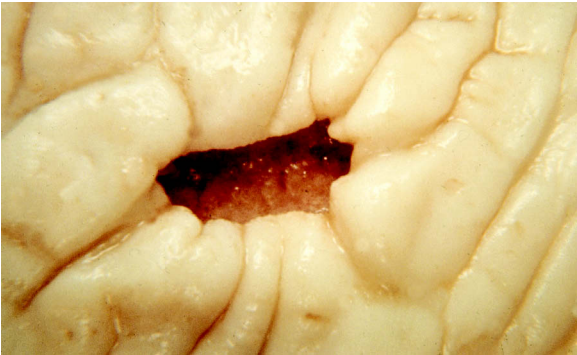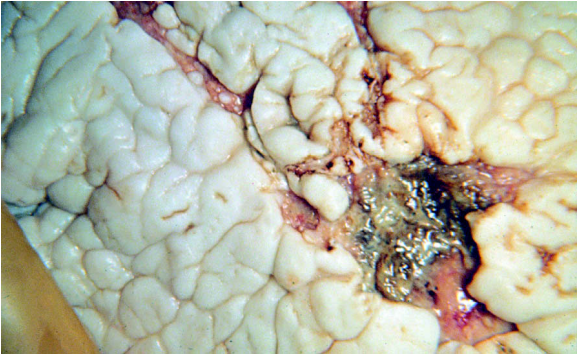


Hemorrhagic gastritis in a harp seal associated with parasitic nematode infection. (Dr. J. Geraci)



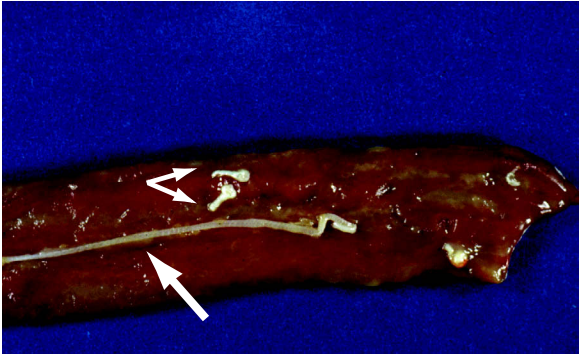
Nematodes in the first stomach chamber of a beluga whale. (Dr. D. Martineau)

STOMACH ULCERS



(Top and bottom) Ulcers in the first chamber of the stomach of a bottlenose dolphin. Ulcers of this kind can occur in any whale, and are caused by parasites or from consumption of foreign objects that may damage the stomach lining. They can occur alone or in small patchy areas throughout the stomach. In the later case, the animal is usually ill. Look carefully for other abnormalities before consuming the meat from an animal with many ulcers in the stomach. (Dr. J. Geraci)

INTESTINAL PARASITES



Intestine of a ringed seal from the western Canadian Arctic showing attached acanthocephalans (small white arrows) and a tapeworm (large white arrow). (Dr. J. Geraci)

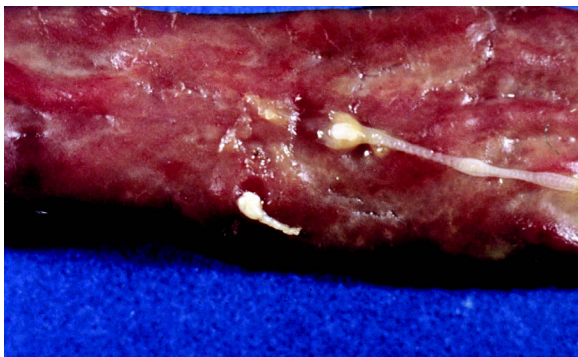Intestinal parasites belong to four broad classes of animals:

- ❖ Cestodes (tapeworms): flat, segmented worms which use hooks or suckers on their head end to attach to the intestinal mucosal lining.
- ❖ Digenea and monogenea (flukes): small, flat worms.
- ❖ Acanthocephala (thorny-headed worms): have spiky projections on their head end which is embedded into the mucosal lining of the intestine.
- ❖ Nematodes (roundworms).

Classes commonly occurring in marine mammals:

- | | |
|------------------|-------------|
| ❖ Cestodes | ❖ Digenea |
| ❖ Acanthocephala | ❖ Nematodes |

INTESTINAL PARASITES



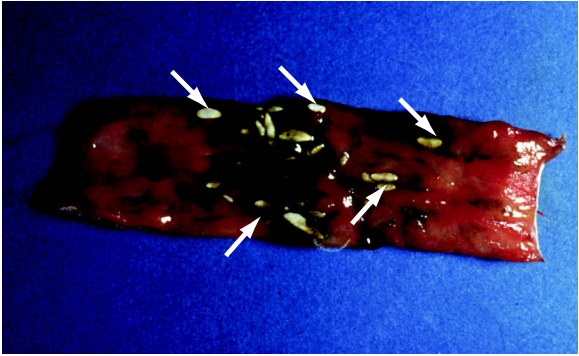
Thorny-headed worms attached to the intestinal mucosa of a ringed seal in western Canadian Arctic. The parasites can be found on the internal or external surface of the intestine and occasionally attached to other surfaces in the abdominal cavity. The parasites need to be distinguished from fish ear bones, which they superficially resemble. (Dr. J. Geraci)

Effects on the host species

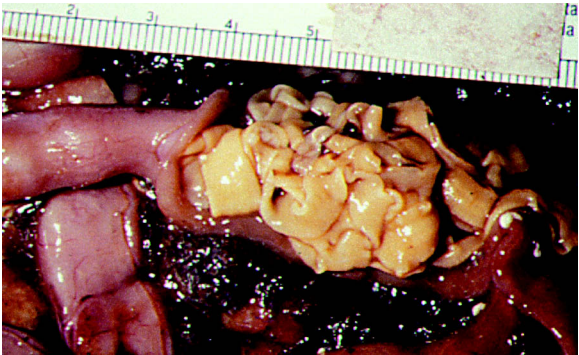
- ❖ These parasites are generally thought to have little effect on their hosts unless they are present in large numbers or occur in non-typical hosts.
- ❖ Acanthocephala may cause small ulcers at the point of attachment.
- ❖ Cestodes may cause problems for their hosts through competition for food or physical blockage of the passage of food.

Human health concerns

- ❖ None



Intestine of a ringed seal from the western Canadian Arctic. Note otoliths (fish ear bones). Otoliths are readily distinguished from *Acanthocephala* - otoliths are not attached and are easily removed. (Dr. J. Geraci)

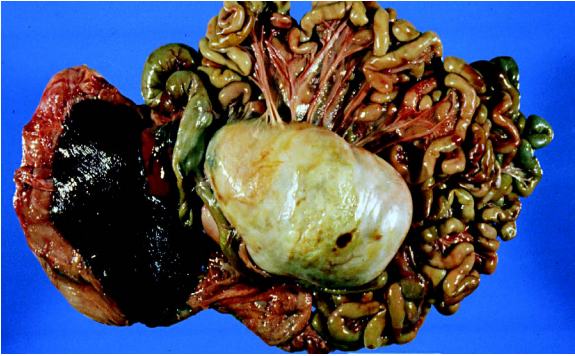

Tapeworm (*Diplogonoporus tetraapterus*) in a ringed seal intestine. (Dr. L. Measures)

Specimens to collect

- ❖ A segment of digestive tract containing the parasites or just the parasites themselves.

LYMPH NODES



Greatly enlarged mesenteric lymph node in a harbour seal. Normal spleen is on the left. (Dr. D. St. Aubin)

What are lymph nodes?

- ❖ Tissue fluids from all organs in the body drain through a series of channels, called lymphatics, which eventually empty into the heart. Along the way, the fluid is passed through a series of filters, called lymph nodes, which are strategically located throughout the body. The fluid is passed through a meshwork of tissue containing cells of the body's immune system, which capture and attempt to deal with foreign invaders such as viruses and bacteria. They form one of the body's first lines of defence against these germs.

Where are they found?

- ❖ Lymph nodes are found throughout the body at strategic locations. For example, there are many near the base of the jaw, draining the face and mouth. A very important group are found in the abdomen in the sheets of connective tissue from which the intestines

hang. These are called the mesenteric lymph nodes and they drain the intestinal tract. Lymph nodes usually occur next to blood vessels. Normally, they are small, often less than 3 cm in length, and may not be obvious.

Enlarged lymph nodes

- ❖ Lymph nodes may become enlarged for many reasons, which include blockage of the flow of fluid out of the node, increased numbers of cells in the node, or leakage of fluid within the node. All of these are signs of disease. The disease may be present only in the area that the node filters. For example, intestinal disease will usually cause enlargement of the mesenteric node. If an animal has a systemic disease affecting many organs in the body, many nodes may be enlarged. Cancer is another cause of enlarged lymph nodes, as cancer cells become trapped in the filtering node.

Effect on the animal

- ❖ The presence of enlarged lymph nodes is evidence of disease, which may be localized or widespread.

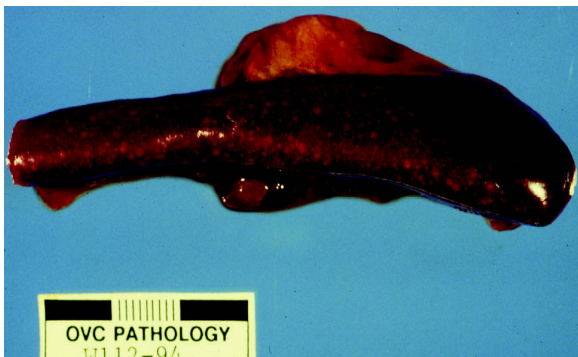Human health concerns

- ❖ Animals with enlarged lymph nodes are likely diseased, and meat from areas of affected nodes should not be eaten. If many nodes are enlarged, the entire carcass is probably not fit for consumption.

Samples to collect

- ❖ Collect the affected nodes and tissues that they drain. Additionally, major organs such as heart, lung, liver, spleen, and kidney are very useful.

SPLEEN



Spleen with many small white spots, which are areas of cell death or inflammation. (Dr. D. Campbell)

What is the spleen?

- ❖ The spleen is an important organ in the body's immune system, which protects the body from disease.
- ❖ The spleen, like the lymph nodes (see Lymph Nodes), acts as a filter, and traps viruses and bacteria as they circulate through the blood.
- ❖ The spleen lies next to the stomach. It is a dark organ. The shape will vary between species and will be curved, oval, or round.

Appearance of a diseased spleen

- ❖ In an animal fighting a viral or bacterial infection, the spleen often becomes larger than normal. An enlarged spleen is normal for diving mammals during a dive, however. While diving, the spleen fills with blood and becomes larger.

- ❖ Cutting into the spleen may reveal many small white spots on the inside of the organ. These white spots may be normal structures that have become more numerous and more active, or they may represent areas of cell death and inflammation.
- ❖ In either case, an enlarged spleen with many white spots indicates active infection, and is evidence that the animal is diseased.

Human health concerns

- ❖ An animal that has a spleen with many small white spots in it is likely sick and unsuitable for consumption.

Samples to collect

- ❖ The spleen or a large sample of it is critical. Other useful samples include lymph nodes and major organs, such as heart, lungs, liver, and kidneys.

RABIES



(K. Burke)

What is rabies?

- ❖ Rabies is a disease of the central nervous system, especially the brain. It is caused by a virus which is shed in the saliva of infected animals. The most common route of infection is through a bite wound in which saliva containing the virus comes into contact with the blood of the animal or person bitten. It is also possible for the virus to cross the soft, moist membranes that are found in the eye, nose, and mouth or to reach the bloodstream when saliva comes into contact with broken skin (e.g. cuts, scrapes). Untreated rabies is a fatal condition in humans.

How can you tell if an animal is rabid?

- ❖ Rabies produces no physical change that can be seen with the naked eye, therefore one cannot determine from gross examination of a carcass whether or not the animal is rabid.
- ❖ Rabies causes animals to behave abnormally. The types

of behaviour seen in rabid animals will vary, depending upon what part of the brain is affected, but may include loss of fear of humans, increased aggressiveness, weakness, and/or paralysis. Infected animals may produce large amounts of saliva (“foaming at the mouth”).

- ❖ The only certain way of determining if an animal is rabid is through laboratory testing of its brain. This is done by federal laboratories in Nepean, Ontario and Lethbridge, Alberta. Antibodies to the rabies virus labelled with a fluorescent dye are applied to frozen sections of brain. Ultraviolet light directed at the section will show if virus is present.

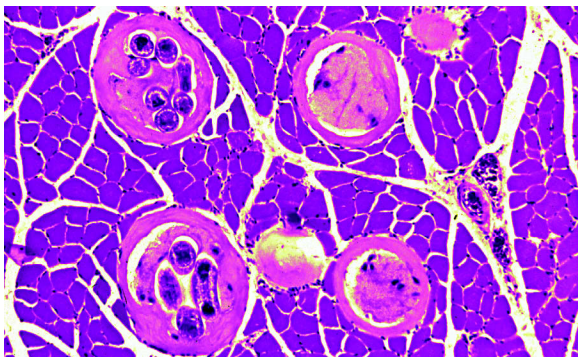
Samples to collect

- ❖ The intact head of the animal is the best sample to submit. The head should be collected and submitted by a wildlife officer.

How to protect yourself

- ❖ Avoid contact with animals displaying abnormal behaviour.
- ❖ If you kill an animal showing abnormal behaviour, try to avoid shooting it in the head, which will make testing of the brain more difficult.
- ❖ Do not handle an animal suspected of having rabies unless you are wearing protective gloves (e.g. rubber).
- ❖ Immediately go to a nursing station or hospital if you have been in contact with an animal that might have rabies.
- ❖ Do not eat the meat from an animal that may have rabies. Do not feed the meat to dogs.

TRICHINELLOSIS



Microscopic view of encysted *Trichinella* larvae in muscle.
(Dr. I. Barker)

What is trichinellosis?

- ❖ Trichinellosis is an infection with the roundworm parasite *Trichinella sp.* This parasite is transmitted from one animal to another by eating meat that contains *Trichinella* larvae found within cysts in muscle tissue. In the Arctic, *Trichinella* cysts occur commonly in polar bear and walrus and less frequently in ringed, bearded, and harp seals, and beluga.
- ❖ An animal becomes infected by eating meat containing *Trichinella* larvae within cysts. The cysts are dissolved in the stomach and larvae develop into adults in the intestines, where they reproduce. Approximately one week after the animal eats cysts, adult female *Trichinella* begin to shed larvae. These larvae enter the circulation and begin to be seeded into muscle tissues throughout the body. In muscle, particularly the

diaphragm, intercostals (muscles between the ribs), and masseter (large muscle of the jaw), larvae form cysts that can remain in this resting form for many years. When the affected animal is killed or dies and the muscle is eaten the cycle begins anew.

How is trichinellosis detected in animals?

- ❖ The cysts are small and not visible with the naked eye, and there usually are no visible changes in the appearance of the meat.
- ❖ Cysts are detected by microscopic examination of muscle tissue.



Walrus eating ringed seal. Scavenging of carcasses of infected walrus or polar bear and predation of ringed seals are possible routes of infection for walruses. (M. Forsberg)

TRICHINELLOSIS

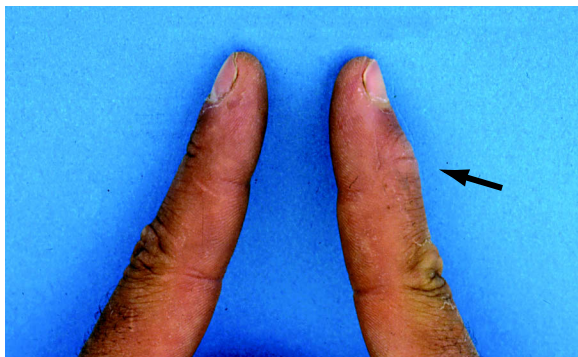
Human health concerns

- ❖ Humans can become infected by eating uncooked meat containing *Trichinella* larvae. The disease in people may involve vomiting, diarrhea, abdominal pain, fever, muscle aches, and rash. Severity of disease depends in part on how many larvae were eaten and on previous exposure. Several outbreaks in humans have occurred in the eastern Arctic as a result of eating uncooked walrus meat.
- ❖ Infected meat can be safely eaten if it is cooked thoroughly, which will destroy the larvae. Meat is safe if it is cooked to a grey colour, the juices run clear, or the internal temperature reaches 170 °F (80 °C).
- ❖ Freezing will not kill larval cysts which may survive at freezing temperatures for many months. Salting, fermenting, smoking, drying, or microwaving meat may not kill cysts.

Samples to collect

- ❖ Collect muscle, especially tongue, masseter, or diaphragm.

MYCOPLASMA



The last joint of the finger on the right is swollen due to *Mycoplasma sp.* (Dr. L. Measures)

What is Mycoplasma?

- ❖ Mycoplasma is a type of bacteria.
- ❖ There are many different species in this group of bacteria, a large number of which cause diseases in humans and animals. Many are carried as normal inhabitants of the mouth or upper respiratory tract and may cause disease if the host is weakened by other diseases or some other stress, and body defences are impaired.
- ❖ *Mycoplasma phocicerebrale* is the species that has been associated with the condition known as seal finger in humans. It has been demonstrated to be a common inhabitant of the gums and teeth of several species of seal (hooded, bearded, harbour, and harp) that live in the Canadian north. In most instances, the animals will show no outward signs of disease.

MYCOPLASMA

What is seal finger?

- ❖ Seal finger, also known as sealer's finger, blubberfinger and speckfinger, is an infection of the hand in which there is severe pain, inflammation, swelling and redness of a joint. There is usually no pus or other discharge, which is quite different from the skin infection caused by sealpox. The affected person usually has had some contact with seals or other marine mammals. The bacteria, which are present in the mouth of the animal, are transmitted to humans through a bite wound or through contact of infected saliva with open skin wounds. The joint affected will typically be close to the point of entry of the bacteria. The condition can usually be successfully treated with antibiotics. Arthritis may develop in cases left untreated.
- ❖ The occurrence of this condition in humans has been associated with exposure to many species of marine mammals, including hooded, bearded, ringed, harp, grey and harbour seals, walrus, and polar bear. In at least one instance, the same species of *Mycoplasma* has been isolated from both the mouth of a seal and from an infected finger bitten by the same seal. This species and other species of *Mycoplasma* and *Ureaplasma* that are commonly found in the mouths of seals are the likely causes of most cases of seal finger involving swollen joints.

How to protect yourself

- ❖ Thoroughly clean and disinfect all bite wounds from marine mammals. Rubber gloves worn while butchering provide protection against entry of bacteria through broken skin.

BRUCELLOSIS

What is brucellosis?

- ❖ Brucellosis is a disease caused by *Brucella*, a bacteria which can infect humans, domestic animals, and wildlife.
- ❖ Several species of *Brucella* exist. The one most commonly reported from the arctic, *Brucella suis* biovar 4, causes a serious disease in caribou, reindeer, muskox, and moose. Arthritis and abortion are two of the more important effects of this disease. Since 1994, evidence of *Brucella* infection in marine mammals has been reported from many locations in the world, including the Canadian Arctic.

Brucellosis in marine mammals

- ❖ *Brucella* infections have been found in a number of species of seals and whales from many locations in the world, including the Canadian Arctic, where it has been isolated from ringed seals, harp seals, and a beluga whale.
- ❖ Antibodies to *Brucella* have also been found in walrus, narwhal, and polar bears demonstrating that these species are also exposed to the bacterium.
- ❖ Little is known of the possible effects of this infection upon marine mammals. Inflammation of the brain has been described due to *Brucella* infections in dolphins from the coast of Great Britain. Other species of *Brucella* are important causes of abortion in domestic animals. *Brucella* infections are a cause of placentitis and abortion in bottlenose dolphins.

BRUCELLOSIS

Human health concerns

- ❖ Many species of *Brucella* can cause disease in humans.
- ❖ The risk of exposure to *Brucella* from marine mammals is not known.

Diagnosis of brucellosis

- ❖ Aborted seal pups and adult seals that are found dead are good cases to examine for *Brucella* as well as many other diseases.
- ❖ If the whole carcass cannot be collected, samples of lung, liver, spleen, kidney, and blood should be collected.
- ❖ The placenta (afterbirth) of aborted seal pups and the reproductive tract and brain from adult seals are also important specimens.
- ❖ Gloves should be worn when collecting samples from animals suspected of having brucellosis.



(Dr. B. Doidge)

MORBILLIVIRUSES

What are morbilliviruses?

- ❖ Morbilliviruses are a group of highly contagious viruses that cause serious disease, often as epidemics with high mortality, in vulnerable populations of animals.
- ❖ Morbillivirus diseases in terrestrial animals include the measles virus of humans and canine distemper virus (CDV) which affects domestic dogs and many wildlife species.
- ❖ Morbillivirus infection was not recognized in marine mammals until 1988. Since that time, there have been several epidemics, often involving thousands of deaths, in seals, dolphins, and porpoises in different parts of the world.
- ❖ Three morbilliviruses are recognized in marine mammals: phocine distemper virus (PDV) affecting seals and other pinnipeds, canine distemper virus which has also affected seals, and cetacean morbillivirus (CMV) affecting dolphins and porpoises.

What are the features of the disease in marine mammals?

- ❖ Morbillivirus infections cause serious illness and death in populations of animals that have not been previously exposed to the virus and therefore have no antibody protection.
- ❖ The most serious effects are upon the brain, lung, and lymphoid system.
- ❖ Affected animals may have discharges from the nose and eyes, breathing difficulties, diarrhea, and listlessness.

MORBILLIVIRUSES

- ❖ Nervous signs include muscle twitching and seizures. Animals are often found dead, however.

Occurrence of morbilliviruses in the Canadian Arctic and North Atlantic

- ❖ Epidemics of morbillivirus infection have not been observed in marine mammals in the Canadian Arctic.
- ❖ Antibodies to the virus, indicating previous exposure, have been found in walrus, polar bear, and grey, harbour, harp, ringed, and hooded seals from the north Atlantic and Arctic oceans. A case of PDV has been reported in a harp seal from the Gulf of the St. Lawrence River. No antibodies have been detected in narwhal and beluga whales, and these species could be particularly vulnerable if exposed to these viruses.

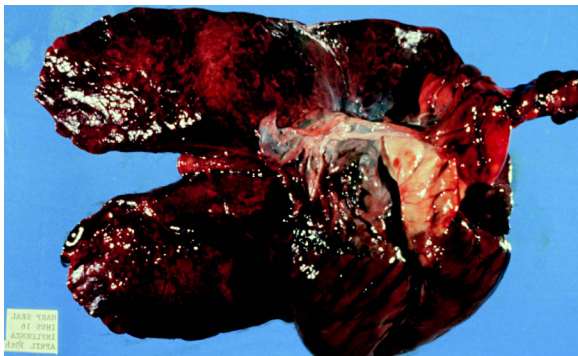
Human health concerns

- ❖ There are no known risks to humans. However, meat from animals that are obviously sick should not be eaten.

Samples to collect

- ❖ Submission of an entire carcass is ideal.
- ❖ If this is not possible, important samples to collect are brain, lung, liver, spleen, lymph nodes, and kidney.
- ❖ The animal may have pneumonia and samples of both affected and unaffected lung should be collected.

INFLUENZA



The lungs of a seal with influenza infection. (Dr. J. Geraci)

What is influenza?

- ❖ Influenza is a contagious disease of the respiratory system, caused by one of a group of diverse but related viruses. The disease occurs in humans, pigs, horses, and birds, and is spread by close contact. The viruses cause a respiratory disease which may include inflammation of the lungs, airways, nasal passages, and eyelids.

Influenza in marine mammals

- ❖ The most important occurrence of influenza in marine mammals was an epidemic of Influenza A in harbour seals off the coast of New England in 1980. These animals had severe pneumonia due to both influenza and a *Mycoplasma* infection.
- ❖ Since that time, other Influenza A viruses have been isolated from harbour seals, a pilot whale, and a minke

INFLUENZA

whale, and an Influenza B virus has been isolated from a harbour seal. The viruses found in marine mammals are most closely related to those in birds.

- ❖ Antibodies to influenza have been detected in beluga and ringed seals from the Canadian Arctic.

Abnormalities caused by influenza

- ❖ Influenza may cause pneumonia and conjunctivitis.

Human health concerns

- ❖ Influenza is transmitted through close contact. An influenza virus from seals caused conjunctivitis in people working with sick animals, but the disease did not last long and did not cause systemic illness.

Samples to collect

- ❖ Samples of affected and normal lung are critical to the diagnosis. Samples of eyelid, airways, and lymph nodes are also useful. In an animal found dead, a wide range of tissue samples, including lung, liver, spleen, lymph node, and kidney should be collected.

EMACIATION



Starving harp seal pup. Note the sagging skin, roughened hair, and emaciation. Severe winter storms separated this seal pup from its mother before it was weaned. Few animals in this condition survive. (Dr. J. Geraci)

What is emaciation?

- ❖ Emaciation is a condition in which the animal has used up its stores of body fat and has become thin, with wasting of muscle mass.

What causes emaciation?

- ❖ Emaciation occurs when an animal uses more energy for its daily activities than it obtains from its food. It is a state that develops over time, as the animal uses up its body reserves. This imbalance of need and supply of energy may be due to many causes. There may be a shortage of food available, or the animal may be too sick or weak to reach food that is present. It may have

EMACIATION

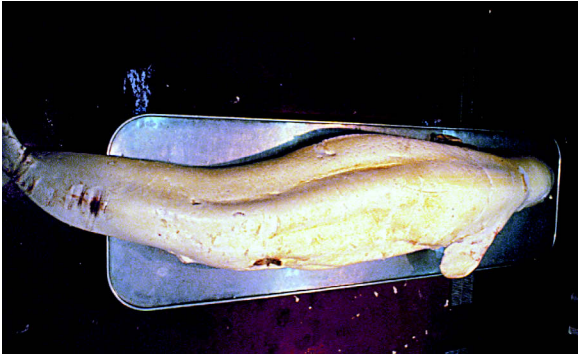


Healthy harp seal pup. (Dr. J. Geraci)

some other disease condition, such as bad teeth or parasites, that makes it unable to make full use of the food it does eat.

Appearance of emaciated animals

- ❖ The fur may look dull and rough and the skin may sag. These animals have little body fat. Muscles may also appear smaller than usual, so that bones appear to stick out more than normal. Even internal organs such as the liver may appear smaller than normal. The digestive tract of emaciated animals may be empty or may contain food items that are of poor quality.



Emaciated beluga being examined for cause of death.
(Dr. D. Martineau)

Species affected

- ❖ Emaciation can occur in any species at any age. Very young and very old animals are more likely to be affected. Animals that are weak and sick because of a previous injury or disease are at greater risk.

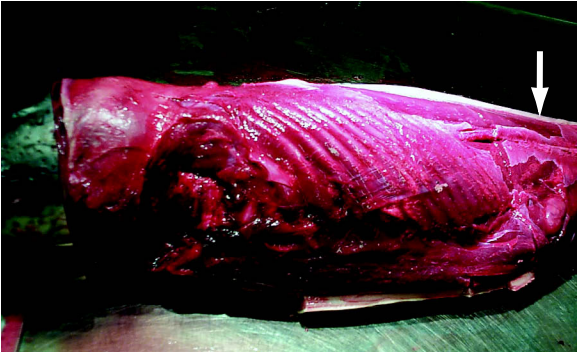Human health concerns

- ❖ If no other disease is present, the meat from emaciated animals is safe for consumption. The quality of the meat may be affected.

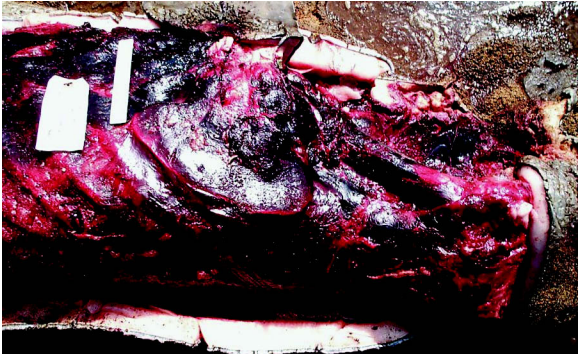EMACIATION



Three young seal pups collected in late June or July. They should be approximately the same size. During some years there are many skinny pups observed, and the time of ice retreat or melting affects this situation. (L. Harwood)



A young Atlantic white-sided dolphin. It was not emaciated - there was good muscle mass in the lumbar region (arrow). The ribs appear prominent but this is likely due to its age. Protruding ribs in young animals are not necessarily indicative of disease, but rather of an immature individual that has not yet built up significant muscle mass. (Dr. L. Measures)

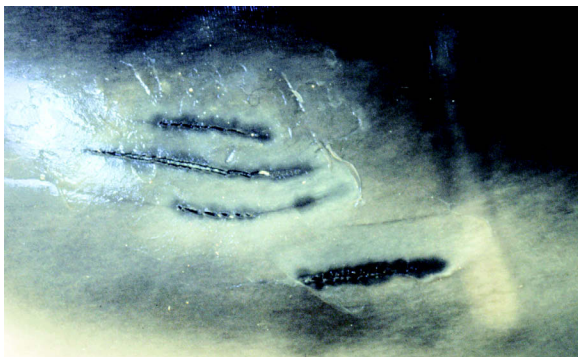

Scapula protruding in an emaciated beluga. Note that the blubber is thick (bottom of picture), but muscle mass has been severely depleted. Arctic marine mammals that are emaciated may still have thick blubber. They may sacrifice muscle mass over energy reserves in the blubber because in frigid arctic waters, loss of blubber equates to imminent death by freezing. Emaciated animals tend to lack muscle in the lumbar region ('hip' area - below the backbone near the anus), shoulder blades (scapula), ribs, and at the base of the neck, behind the head. (Dr. L. Measures)

Samples to collect

- ❖ An emaciated animal should be thoroughly checked for signs of disease and injury.
- ❖ Samples of any apparently abnormal tissues should be collected.
- ❖ The femur (thigh bone) of polar bears can be collected to evaluate the state of fat depletion of the bone marrow in that species.

INJURIES



“Rake marks” are a series of parallel cuts that may be found on the skin of dolphins and toothed whales. They are caused by tooth contact while playing or fighting with other animals. These injuries can be shallow or deep cuts, and may be associated with bleeding when fresh. Commonly, they are seen as scars over most of an animal’s surface. (Dr. J. Geraci)

Injuries

- ❖ Many wild animals, including marine mammals, will suffer injuries that do not kill them.
- ❖ When these animals are harvested, the evidence of the injury may still be present in the carcass, and will be recognized as something abnormal. Injuries detected at the time of harvest may be quite recent or they may have happened some time ago.
- ❖ Common injuries include skin wounds, bruising, broken bones, and damage to muscle.

What are the common causes of injuries?

- ❖ **Humans:** non-fatal hunting wounds (gunshot, harpoon, etc.) and collisions (boats).
- ❖ **Animals of the same species:** fighting injuries are most common in males, especially in polar bear, walrus, and some seals. Common injuries of this sort include bite wounds and claw marks.
- ❖ **Animals of other species:** animals that survive predatory attacks may be left with wounds, particularly to the skin and muscle. These also include bite wounds and claw marks but such injuries are generally in different locations than those caused by fighting with another animal of the same species, for example on the abdomen rather than the face.

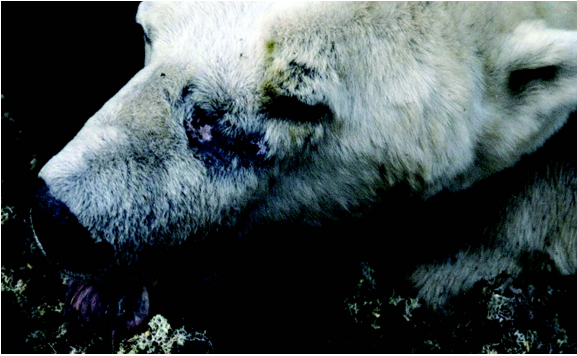Effects on the animal

- ❖ The significance of an injury to an animal will depend upon its severity, its location, and its effect upon the function of the tissue injured. Open wounds can become infected or be a source of blood loss. Fractures will cause difficulty in using the bone involved and may lead to reduced hunting success, or increase the animal's risk of being shot or taken by a predator. Animals with injuries may be in poor body condition.

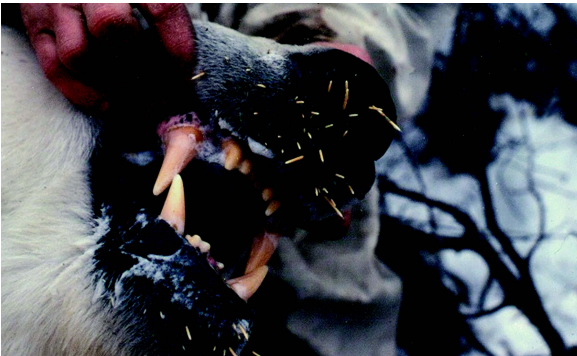Human health concerns

- ❖ Meat of injured animals is safe for human consumption but may be of reduced quality because of emaciation or scarring.
- ❖ The animal may have been injured because it was already sick and signs of other disease should be looked for.

INJURIES



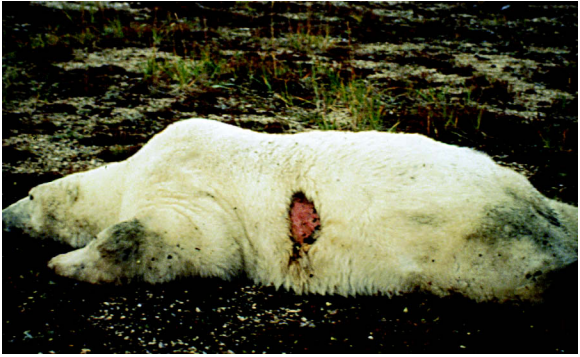Male polar bear with a scar on its nose. (Dr. I. Stirling)



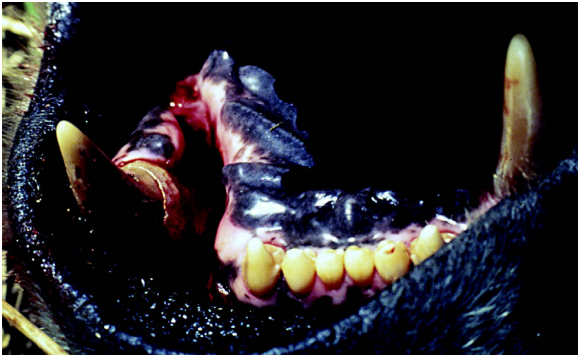Polar bear quilled by porcupine. (Dr. I. Stirling)

Samples to collect

- ❖ Collect samples of the injured area plus surrounding normal tissue. If more widespread disease is suspected, a sample of organs that includes heart, lung, liver, kidney, and spleen should be collected.

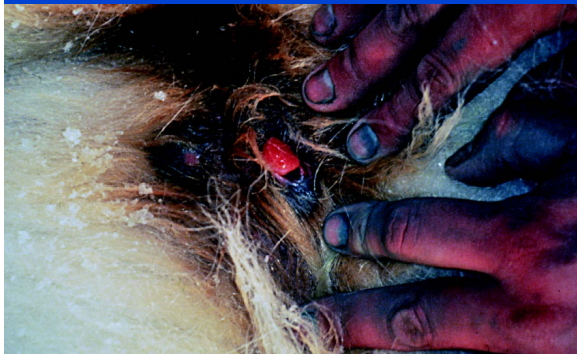

Large (approximately 35 cm in diameter) circular wound on the left side and abdomen of an anesthetized 19 year old adult male polar bear. The wound was almost perfectly circular and clean cut. It is suspected that the bear was bitten by a Greenland shark while swimming. The wound appeared to heal without complication. (Dr. M. Cattet)



Male polar bear with fractured mandible involving the lower right canine. This condition likely occurred as a result of fighting with other male polar bears, or preying on something very large. (Dr. M. Cattet)

FEMALE PSEUDOHERMAPHRODITE POLAR BEARS



Ossified, enlarged clitoris of a 2 year old female polar bear. Her female sibling showed similar masculinization of her external genitalia. Such an animal is called a pseudohermaphrodite. (Dr. O. Wiig)

What is a female pseudohermaphrodite?

- ❖ A female pseudohermaphrodite is an animal that is genetically female, but has both male and female external genitalia.

Species affected

- ❖ This condition has been described in several species of bears including polar bears.

Description of the abnormality

- ❖ Female polar bears have been found with a penis like structure inside a normal vaginal opening.

Importance of the condition

- ❖ It is not known how commonly this condition occurs nor whether it affects the animal's ability to reproduce.

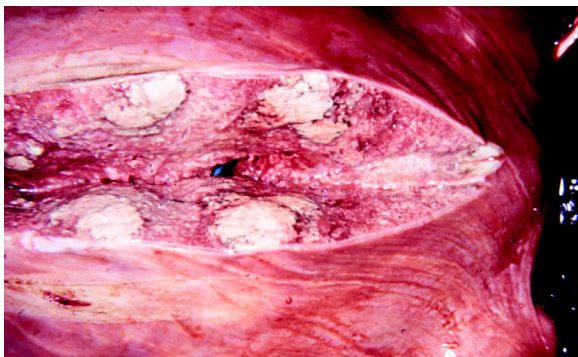
What causes pseudohermaphroditism?

- ❖ The cause of this condition is not known. It has been hypothesized that it is due to the endocrine-disrupting effects of environmental pollutants. It is also possible that it is a naturally occurring anatomical abnormality in bears.

Samples to collect

- ❖ Collect the entire reproductive tract including the uterus and ovaries in bears that have been killed. Photographs of the condition are also useful.
- ❖ Tissues to collect for an analysis of chemical contaminants include liver, kidney, and fat.

ABSCESSSES



Bacterial abscesses in the lung of a beluga whale. Findings such as this suggest a systemic illness. (Dr. J. Geraci)

What is an abscess?

- ❖ An abscess is a localized area of infection that the body has attempted to control and wall off from surrounding normal tissue. This results in a pocket of pus, surrounded by a fibrous tissue capsule.

Where do abscesses form?

- ❖ Abscesses can form wherever bacteria have become established. For example, a bite wound can introduce bacteria into muscle and an abscess can form if the wound does not drain. Bacteria that have established at one site in the body may then travel in the bloodstream to infect other locations. This is a common route for the development of abscesses in tissues such as lung and liver.

Effects on the animal

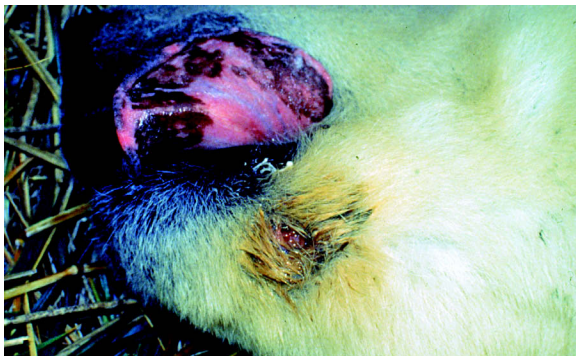- ❖ An abscess may interfere with the normal function of the tissue in which it is located. For example, numerous abscesses in the lungs may interfere with breathing and the ability to exercise. In contrast, an isolated abscess in muscle may have little or no effect on the animal.

Human health concerns

- ❖ If abscesses are numerous and occur in many different tissues, the animal is probably not fit for consumption. If there is only a single abscess or a few abscesses and they all occur in the same part of the body, then they can likely be cut out and the remainder of the carcass can be used.
- ❖ Abscesses contain bacteria that may be harmful, and therefore should not be consumed.


Samples to collect

- ❖ Collect tissues containing abscesses (unopened if possible) as well as some surrounding tissue. Filtering organs (lung, liver, kidney, spleen) are also useful.



Adult polar bear with mandibular abscess arising from a damaged molar on the left side of the jaw. (Dr. M. Cattet)

TUMOURS



Bulbous growth on polar bear's face. (Dr. I. Stirling)

What is a tumour?

- ❖ A tumour is an abnormal mass, or swelling, of tissue that results from the uncontrolled growth of cells. Tumours are classified on the basis of the cell type from which they are formed, and by their behaviour. Tumours that invade surrounding tissue or spread to other areas or organs of the body are described as malignant or cancerous, while those that grow slowly in one location are benign.

What causes tumours?

- ❖ While some tumours have known causes, in most instances the cause is not known. Seeking the cause of tumours is an important field in cancer research, particularly in human medicine. Less is known about the tumours of animals. In some cases, tumours may be caused by viruses. Other tumours likely result from

the combined effects of genes and the environment, including foods, chemical exposures, and injuries.

How common are tumours in marine mammals?

- ❖ Tumours are generally rare in wildlife, including marine mammals. Many, however, likely go undetected because the animals affected by tumours may die in the wild and are never examined by anyone. Tumours occur most commonly in older animals.

What kinds of tumours occur in marine mammals?

a) Fibromas and papillomas

- ❖ These are the most common kinds of tumours, particularly in the skin, in marine mammals. Both are benign. They are somewhat similar in appearance, being firm round masses of varying size. Fibromas are firmly rooted in the skin and underlying tissue while papillomas (warts) often grow outward from stalks.
- ❖ Fibromas are the most commonly reported tumour in whales and dolphins. Papillomas have been reported as occurring on the skin, penis, genital slit, vagina, tongue, pharynx, and first gastric compartment in both baleen and toothed whales.

TUMOURS

b) Malignant tumours

- ❖ The greatest number of malignant tumours in marine mammals have been described in the belugas of the St. Lawrence River. This population of animals is exposed to many industrial chemicals which have been discharged into the river. Some of these chemicals are known to cause cancer.
- ❖ The most common types of tumour described in St. Lawrence belugas are varieties of carcinomas. A carcinoma is a malignant tumour arising from the epithelium, which forms both the skin and the internal lining of many organs, including the stomach and reproductive tract, and the solid portions of many other organs such as the liver and endocrine glands (e.g. thyroid, adrenal).
- ❖ Malignant tumours may grow in uncontrolled fashion, invading surrounding tissues and perhaps interfering with the normal function of the organ in which they occur. For example, a tumour in the stomach may invade the wall and extend into the stomach chamber where it may block the flow of food.

What do tumours look like?

- ❖ The appearance of a tumour will vary depending upon its location and the cell type of which it is made. Tumours are often discovered when butchering an animal. The tumour will stand out as an abnormal appearing mass within an organ. It may be either firmer or softer than the surrounding tissue. It may be enclosed in a firm capsule or it may grow either outward or into the surrounding tissue.

Is it safe to eat an animal that has a tumour?

- ❖ The answer to this question will depend upon the type of tumour, where it occurs and the general body condition of the animal. For example, a small or encapsulated tumour found in one tissue could easily be cut out and the remainder of the animal safely consumed. However, if a tumour has invaded deeply or spread widely in the body and the animal is in poor condition, it would likely be best not to eat the animal.

How is a tumour diagnosed?

- ❖ Tumours are classified by cell type and behaviour by examining sections of them microscopically.

What samples should be taken?

- ❖ If possible, the entire tumour and a margin of normal surrounding tissue should be collected. If this is too large, a section of the tumour and its margin with normal tissue would be the next best sample.
- ❖ It is useful to include samples of organs such as lung, liver, and spleen that filter blood, and local lymph nodes, since they are likely places for tumours to spread. Examination of these tissues helps to decide whether or not a tumour is malignant.

SOURCES OF FURTHER INFORMATION

Nunavut Wildlife Service
Department of Sustainable Development
Government of Nunavut
Box 1000, Station 1170
Iqaluit, NU. X0A 0H0.

Government of the Northwest Territories
Resources, Wildlife and Economic Development
Wildlife and Fisheries
5th Floor, Scotia Building
600, 5102-50th Avenue
Yellowknife, NT. X1A 3S8.

Nunavik Research Centre
Makivik Corporation
PO Box 179
Kuujuuaq, QC. J0M 1C0.

Fisheries and Oceans Canada
Institut Maurice Lamontagne
850 Route de la mer
Mont-Joli, QC. G5H 3K6.

Department of Fisheries and Oceans Canada
501 University Crescent
Winnipeg, MB. R3T 2N6.


Canadian Cooperative Wildlife Health Centre

Atlantic Region
Pathology and Microbiology
Atlantic Veterinary College
550 University Avenue
Charlottetown, PEI. C1A 4P3.
902-566-0667 or 902-566-0959

Quebec Region
FMV, Université de Montréal
3200, rue Sicotte
Saint Hyacinthe, QC. J2S 7C6.
514-773-8521 x 8347/8307

Ontario/Nunavut Region
Pathobiology, OVC,
University of Guelph
Guelph, ON. N1G 2W1.
519-823-8800 x 54556/54662

Western and Northern Region
Veterinary Pathology, WCVM
University of Saskatchewan
52 Campus Drive
Saskatoon, SK. S7N 5B4.
306-966-5099



Kara Vlasman, BSc MSc, is a wildlife biologist with a background in aquatic and marine biology and a graduate degree in wildlife ecology. She is currently a research assistant with the Ontario/Nunavut Region, Canadian Cooperative Wildlife Health Centre, Ontario Veterinary College, University of Guelph, and also works as a wildlife ecology consultant.

Douglas Campbell, BSc MPI DVM DVSc, is a veterinarian with a background in wildlife biology and land use planning, and an advanced degree in wildlife diseases. He is Staff Pathologist, Ontario/Nunavut Region, Canadian Cooperative Wildlife Health Centre, Ontario Veterinary College, University of Guelph.

The CCWHC is a network based in Canada's four veterinary colleges that applies the veterinary medical sciences to benefit wildlife conservation and management, and develops and uses knowledge about wildlife health and disease to the betterment of human health and the health of domestic animals. The CCWHC coordinates Canada's national program of wildlife disease surveillance and provides educational programs, information and consultative advice to government and non-government agencies and to the public. The CCWHC is supported by Environment Canada, Canada's four veterinary colleges and their home Universities, The Governments of Canada's 10 Provinces and 3 Territories, Heritage (Parks) Canada, Health Canada, The Canadian Food Inspection Agency, Fisheries and Oceans Canada, AgrEvo Canada Inc., DowElanco Canada Inc., Syngenta Crop Protection Inc. Novartis Crop Protection, Ducks Unlimited Canada and the Canadian Wildlife Federation. The Max Bell Foundation provided a founding grant that supported the establishment of CCWHC.

Headquarters Office

Department of Veterinary Pathology
Western College of Veterinary Medicine
University of Saskatchewan
52 Campus Drive, Saskatoon, SK. Canada
S7N 5B4

Email: CCWHC@usask.ca
Phone: (306) 966-5099

